Rishi Vansh

All India Institute of Medical Science Rishikesh **AIIMSR**

Department Of Pediatric Genetic -division

Volume Issue 37, June 2023

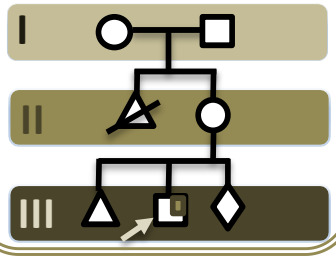

From the desk of Editor

The genetic division of the Pediatric Department is publishing a monthly newsletter for faculty and residents. The newsletter is related to genealogical parlance and is a deliberate attempt to enhance awareness of genetic disorders with recent updates.

Neurometabolic/Intellectual Disability/ X-Linked/ AIFM1 related disorder including Cowchock syndrome (CMTX4) / (COWCK)

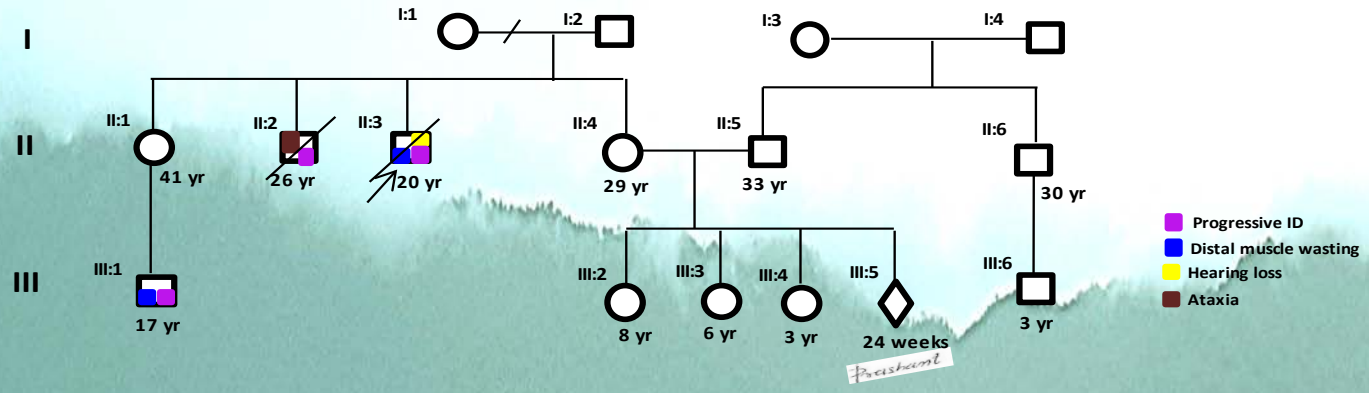

AIFM1 Protein function besides NADH oxidoreductase

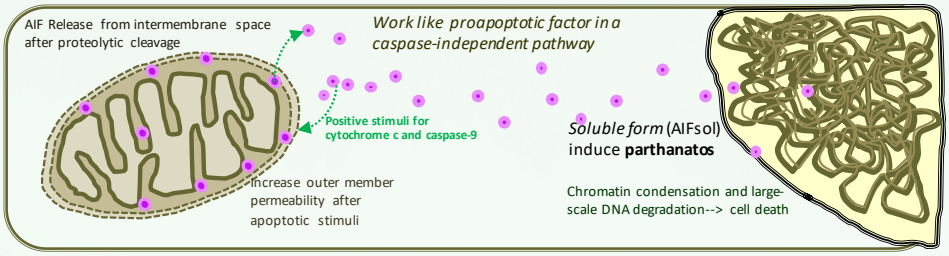

- **Parthanatos:** A caspase-independent programmed cell death, due to over threshold activation of poly (ADP-ribose) nuclear enzyme [PARP-1synthetase 1 or poly (ADP-ribose) transferase 1]

Insight:

1. What are routine laboratory abnormalities in COWCK patients?
2. Does the COWCK case clinically present as spastic cerebral palsy?
3. What are the allelic disorders of AIFM1?
4. Is there any role of riboflavin (vitamin B2) in the management of the COWCK patient?
5. How would you like to counsel for case III:5, especially for antenatal testing?

Protein sequence

MFRCGGLAAGAL
KQKLVPLVRTVC
VRSPRQRNRLPG
NLFQRWHVPLEL
QMTRQMASSGAS
GGKIDNSVLVLIV
GLSTVGAGAYAYK
TMKEDEKRYNER
ISGLGLTPEQKQK
KAALSASEGEEVP
QDKAPSHVPFLLI
GGGTAAFAAARSI
RARDPGARVLIVS
EDPELPYMRPPLS
KELWFSDDPNVT
KTLRFKQWNGKE
RSIYFQPPSFYVSA
QDLPHIENGGVA
VLTGKKVVQLDV
RDNMVKLNDGSQ
ITYEKCLIATGGT
PRSLSAIDRAGAE
VKSRTTLFRKIGD
FRSLEKISREVKSI
TIIGGGFLGSELAC
ALGRKARALGTE
VIQLFPEKGNMG
KILPEYLSNWTM
EKVRREG
VKVMPNAIVQSV
GVSSGKLLIKLKD
GRKVETDHIVAA
VGLEPNVELAKT
GGLEIDSDFGG
FRVNAELQARSNI
WVAGDAACFYDI
KLGRRRVEHHDH
AVVSGRLAGENM
TGAAKPYWHQS
MFWSDLGPDVGY
EAIGLVDSSLPTV
GVFAKATAQDNP
KSATEQSGTGIRS
ESETESEASEITIP
PSTPAVPQAPVQ
GEDYGKGVIFYLR
DKVVVGIVLWNIF
NRMPIARKIIKDG
EQHEDLNEVAKL
FNIHED

- Each Exon in different colours (Residue overlaps splice site)

Plausible tenets:

Gene: AIFM1(Xq26) Genomic coordinates (GRCh38) **X:130,129,362-130,165,841**

- **A flavoprotein, flavin adenine dinucleotide (FAD)-dependent oxidoreductase,** having 31 splice variants, 206 orthologues, 7 paralogues
- Transcript: **Coding exons: 16**; **2,222 bps**, 44 domains, and features, Protein has 613 amino acids, with a molecular weight of 66901 Da.
- Apoptosis regulator, especially caspase-independent cell death. Respiratory chain biogenesis regulator through controlling CHCHD4 mitochondrial import
- A FADH2-NAD charge transfer complexes (CTC), also an oxidation resistance complex, having a NADH induce reduced homodimer of AIFM1

Clinical phenotypes: XL recessive MOI, minor changes in NCV, EMG, and hearing loss reported in a few women

Charcot-Marie-Tooth disease (CMTD): the most common hereditary neuromuscular disorder, prevalence of around 1 in 2,500 people. Only 7%–10% of CMT is inherited as an X-linked trait (CMTX)

Phenotype (MIM number)	Age of onset	Characteristic features
Combined oxidative phosphorylation deficiency 6 (COXPD6)(300816)	< infancy even in utero	Only X linked COXPD out of - **PS609060 - 57 Entries** significant Hypotonia, areflexia, severe psychomotor development, seizures, involuntary movements (basal ganglia involvement), hypertrophic cardiomyopathy
Cowchock syndrome (310490)	Infancy to adolescent	Charcot-Marie-Tooth disease - **PS118220 - 81 Entries**, **CMT X1-6** Progressive Neuropathy (periphery, auditory- usually presenting feature) & cerebral leukodystrophy & cerebellar atrophy
Spondyloepimetaphyseal dysplasia, X-linked, with ***hypomyelinating leukodystrophy** (SEMDHL) (300232)	Post infancy	Predominantly skeletal dysplasia with short stature, joints deformities, visual defects, slowly progressive neurocognitive regression
Deafness, X-linked 5(300614)	Childhood	Only X linked Auditory neuropathy in - **PS609129 - 4 Entries and Deafness**, X-linked - PS304500 - 7 Entries late onset, slowly progressive diffuse peripheral sensory neuropathy

***Leukodystrophy, hypomyelinating (LH)- PS312080 - 26 Entries, only XL LH- Pelizaeus-Merzbacher disease, XLR**
Overlapping phenotype with cerebral palsy as spastic quadriplegia, developmental delay, & periventricular changes

Clinical Severity order of AIFM1 Protein related disorder: COXPD6> Cowchock syndrome> SEMDHL >Deafness, X-linked 5

Under electron microscopy Mitochondrial image: shape alteration as large, irregular, concentric cisternae along with predominantly subsarcolemmal aggregates due to an increase in mitochondria numbers

Counsel the family for case III:5- Counselling the parent for a 24-week-old fetus without proband mutation in the family member & uncertainty of the carrier status of the mother: Just discuss the statistical possibility of the affected fetus; it will be 25 % if the mother is a carrier for the disease, and it will be likely as the general population in case of mother's report comes out negative. Avoid discussing carrier possibility in the fetus, specifically with X- Linked disorder. Limitations & time-bound benefits of the test must be discussed in the same setting.

Thought Riveting:

- ***What could be a cause for predominantly skeletal system involvement in SEMDHL?***
- ***Can Anti-AIFM1 therapy induce parthanatos in dysplastic cells?***
- ***What chemical molecules can induce the soluble form (AIFsol) of AIFM1 protein from the inner-membrane-anchored form (AIFmit)?***
- ***What is the ethical dilemma for antenatal counselling of X-linked disease?***
- ***Which vitamins help in the modulation of mitochondrial bioenergetics?***

Author: Dr Prashant Kumar Verma
Reviewer: Dr. Raksha Ranian