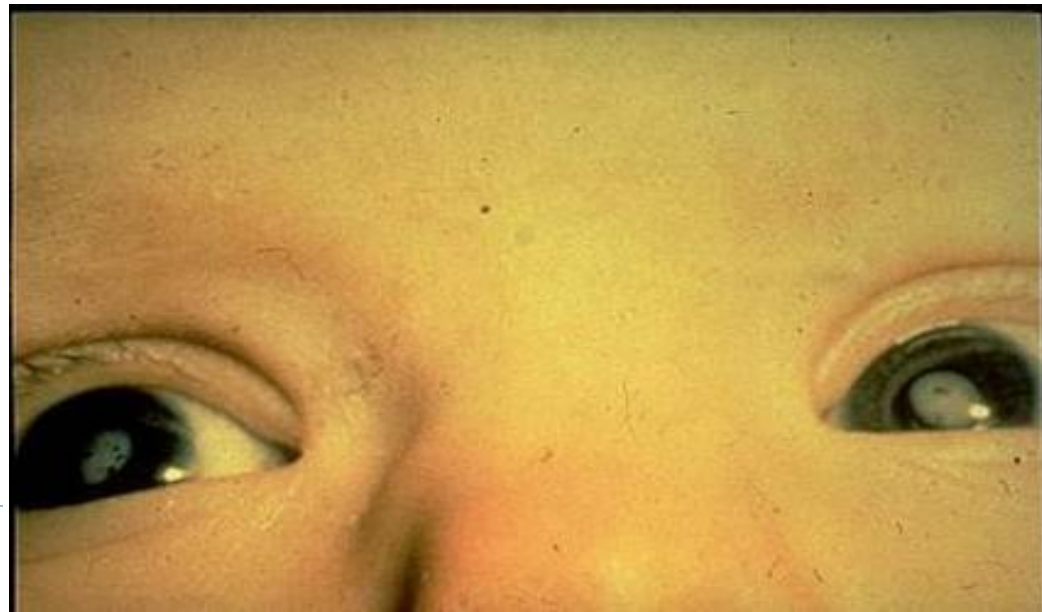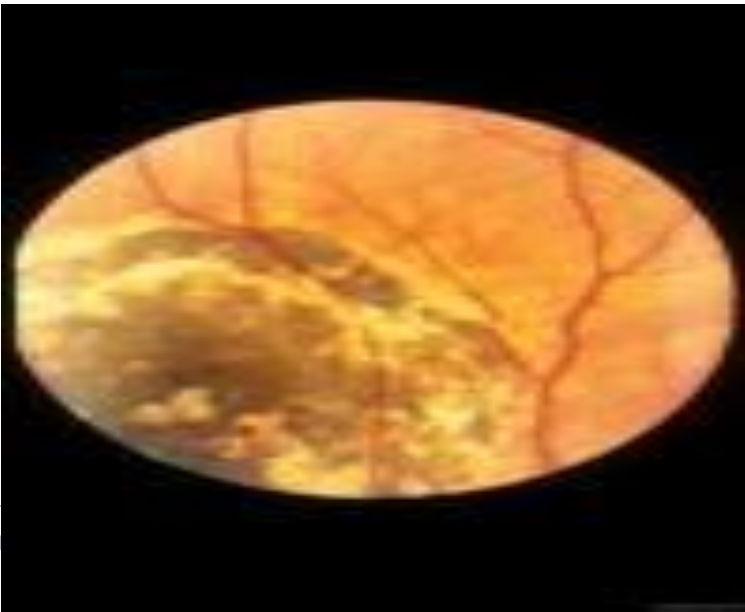


INTRA UTERINE INFECTIONS

8 /02/18,

**Dr. Swathi Chacham DM(neonatology,PGIMER),
Additional Professor,AIIMS,Rishikesh**



Learning Objectives

- ▶ **Common IU infections**
- ▶ **When to suspect IU infection**
- ▶ **Hep B vertical transmission, Congenital rubella syndrome ,Congenital toxoplasmosis**
- ▶ **Diagnosis , management & prevention**



TORCH-Coined by Nahmias in 1974, now TORCHES CLAP

- To - Toxoplasma,
- R - Rubella,
- C - Cytomegalo virus,
- H - HSV,
- E - Enterovirus,
- S - Syphilis
- C - Chicken pox
- L - Lyme's
- A - AIDS
- P - Parvo virus B 19



What are common IU infections??

- ▶ Two major categories: congenital& perinatal
- ▶ congenital: transmitted to the fetus in utero
- ▶ Perinatal :acquired intrapartum / in the post natal period



ROUTES OF VIRAL INFECTIONS OF FETUS & NEONATE

CONGENITAL

PERINATAL

POSTNATAL

CMV, TOXOPLASMA

HSV

VARICELLA

PARVO B19

RUBELLA

ENTEROVIRUS, HEP- B&C,

HEP- A



Prevalence:HBV infection

- ▶ 5% of the world's population is chronically infected with hepatitis B
- ▶ India: Prevalence rate for HBsAg seropositivity 2-7 %
- ▶ Pregnant women : 0.9% and 11.2
- ▶ HBeAg seropositivity of 30% -56.8%



Carrier status

- ▶ 90% of affected infants develop chronic infection
- ▶ 30-50% of under-five children and 6% of children above five years of age .
- ▶ Chronic hepatitis B infection acquired in childhood carries a 25% risk for development of chronic liver disease, cirrhosis or hepatocellular carcinoma .
- ▶ Hence, it is imperative to prevent mother to child transmission.



Pregnancies with HBV

- ▶ Risk of chronic infection $\propto 1/\text{age}$ (inversely proportional to age)
- ▶ 90% carriage rate for neonatal infection &
- ▶ 40-75 % vertical transmission rate
- ▶ Intrapartum route $>$ transplacental $>$ breastfeeding



Hep B : Strategies for prevention

- ▶ Universal screening of pregnant women
- ▶ Case management of HBsAg-positive mothers and their infants
- ▶ Elective LSCS, continue breastfeeding



- ▶ Immunoprophylaxis : All infants born to mothers with positive HBsAg , should receive HBIG (within 12-24 hrs of birth)(0.5ml)+ Hep B vaccine(0.5ml=10 μ gm)(within few hrs of birth) & Repeat Hep B vaccine @ 1 & 6 months.
- ▶ Universal immunization : 2 course (6 doses)

Identification in a pregnant women

- When to suspect?
- Three strategies -
 - A) Routine / universal screening
 - B) Women with high risk factors

C) Symptomatic women

- a) Multiple partners
- b) Repeated BT's
- c) Partner with STD
- d) Unhygienic food habits
- e) Rubella non-immune
- f) Occupational exposure



Contd...

Maternal H/o

- ▶ Contact with a known infected case during pregnancy
- ▶ History of non vesicular rash [Rubella/ parvo virus]
- ▶ Vesicular rash [varicella & herpes simplex]
- ▶ History of recurrent abortions



Contd...

Neonatal manifestations

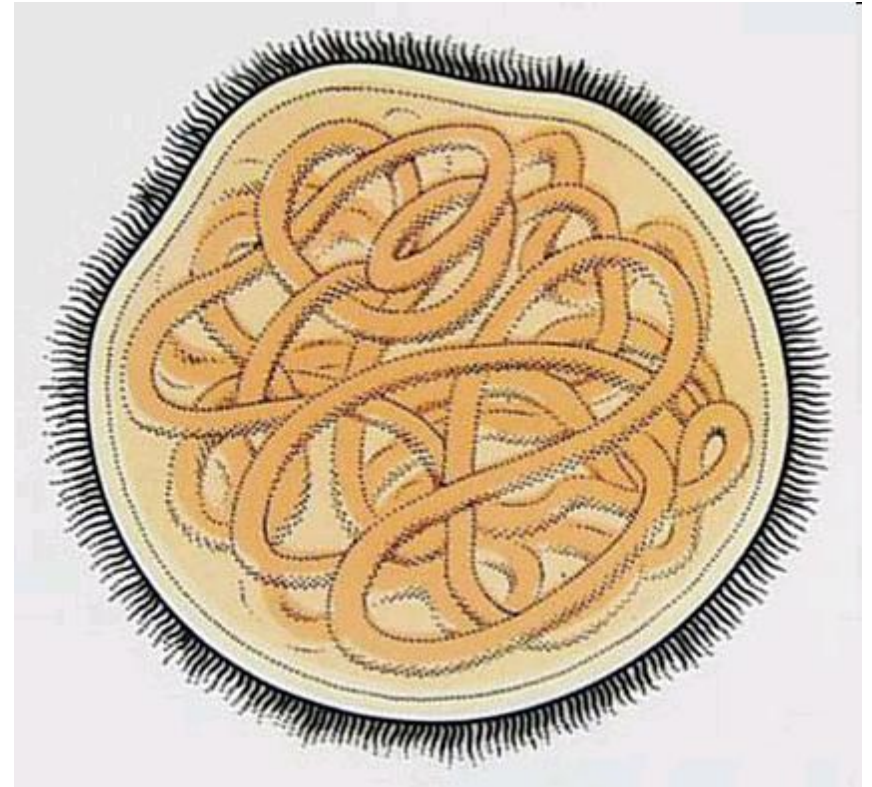
- ▶ PDA in a term/ near term neonate(Rubella)
- ▶ Clinical stigmata of IU infections: SFD, hepatosplenomegaly, blue berry muffins, microcephaly,chorioretinitis, cataracts
- ▶ Late onset neonatal cholestasis



CONGENITAL INFECTION	MAIN FINDINGS
Rubella	cataracts, cloudy cornea, blue berry muffins, PDA, PPS
CMV	microcephaly, periventricular calcifications, jaundice, snhl
Toxoplasma	hydrocephalus, generalized calcifications, chorioretinitis
Syphilis	osteocondritis, periosteitis, snuffles, rash
Herpes	skin lesions, keratoconjunctivitis, acute encephalitis
Varicella	limb hypoplasia, scarring, GI tract atresis
LCMV	hydrocephalus, chorioretinitis, ic calcifications

Rubella: German Measles

- ▶ Rubella is also called as 3 day Measles or German Measles.
- ▶ Family – **Togaviridae**
- ▶ Genus - **Rubivirus**
- ▶ In general belong to Togavirus group



Post natal Rubella

- ▶ Occurs in Neonates and Childhood
- ▶ Adult infection - through mucosa of the upper respiratory tract ----cervical& occipital lymphnodes
- ▶ Viremia - after 7 – 9 days& Lasts for 13 – 15 days
- ▶ Leads to development of antibodies
- ▶ The appearance of antibodies coincides the appearance of rash. suggesting immunologic basis for the rash
- ▶ In 20 – 50 % cases of primary infections are subclinical





RUBELLA

- Incidence (Indian scenario):
- Singh et al (1999):
 - Seroprevalence of Rubella 90-95% (IgG) and only 5-10% are non-immune
- Tarbudkar et al (IJMM 2003):
 - IgG seropositivity – 67%
 - IgM seropositivity – 23%



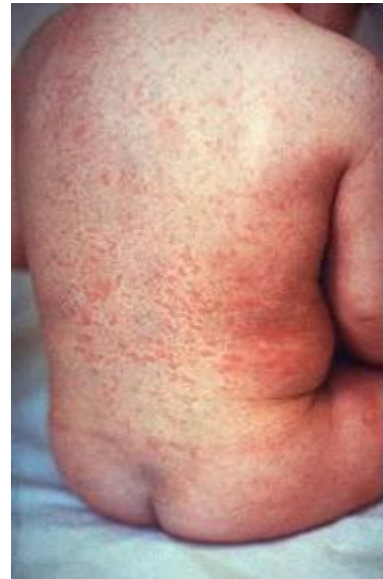How Adults acquire Infection ??

- ▶ Acquired rubella - via airborne droplet emission -from the upper respiratory tract of active cases.
- ▶ Virus – also present in urine, feces and on the skin.
- ▶ No carrier state: exists entirely in active human cases.
- ▶ The disease has an incubation period of 2 to 3 weeks.

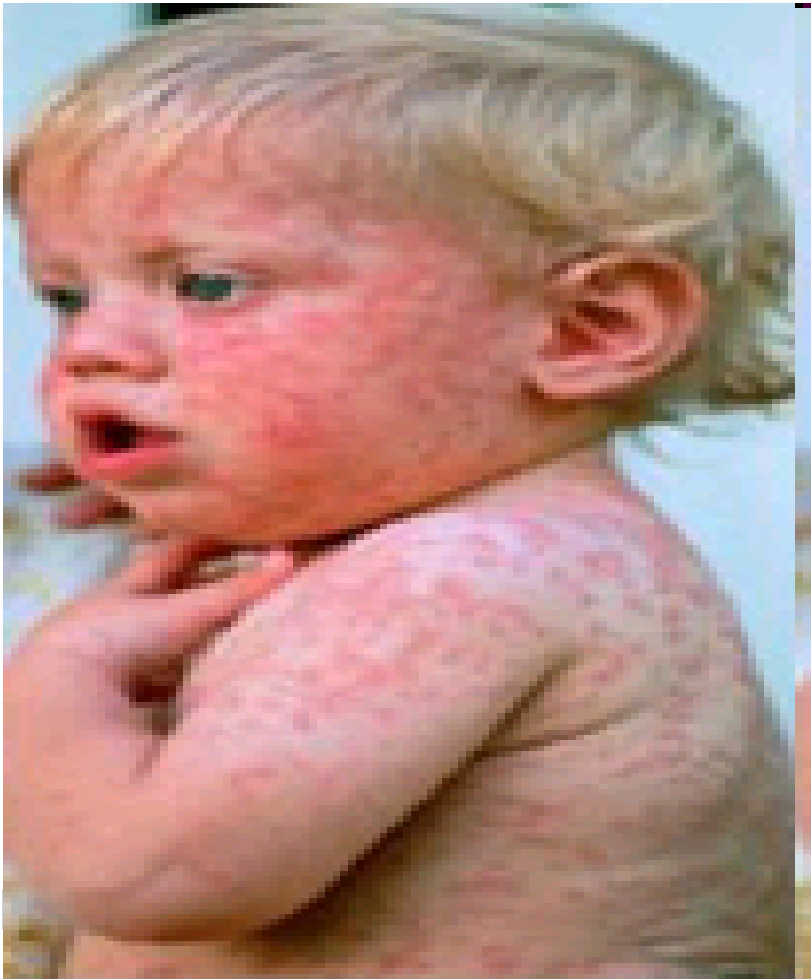

Clinical manifestations

- ▶ Malaise
- ▶ Low grade fever
- ▶ Morbilliform rash
- ▶ Rash starts on Face & Extremities
- ▶ Rarely lasts more than 5 days
- ▶ No features of the rash give clues to definitive diagnosis of Rubella.



Rubella rashes

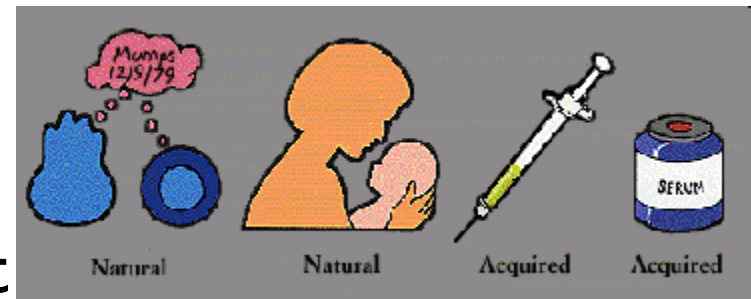


Empty rectangular box for text input.

Empty rectangular box for text input.

Acquisition of immunity

- ▶ Antibodies appear in serum as rash appears & antibody titers rise as rash fades
- ▶ Rapid rise in 1 – 3 weeks
- ▶ Rash with detection of IgM antibodies -indicates recent infection.
- ▶ IgG antibodies persist Life long
- ▶ maternal antibody protection-
- ▶ for 4 – 6 months.



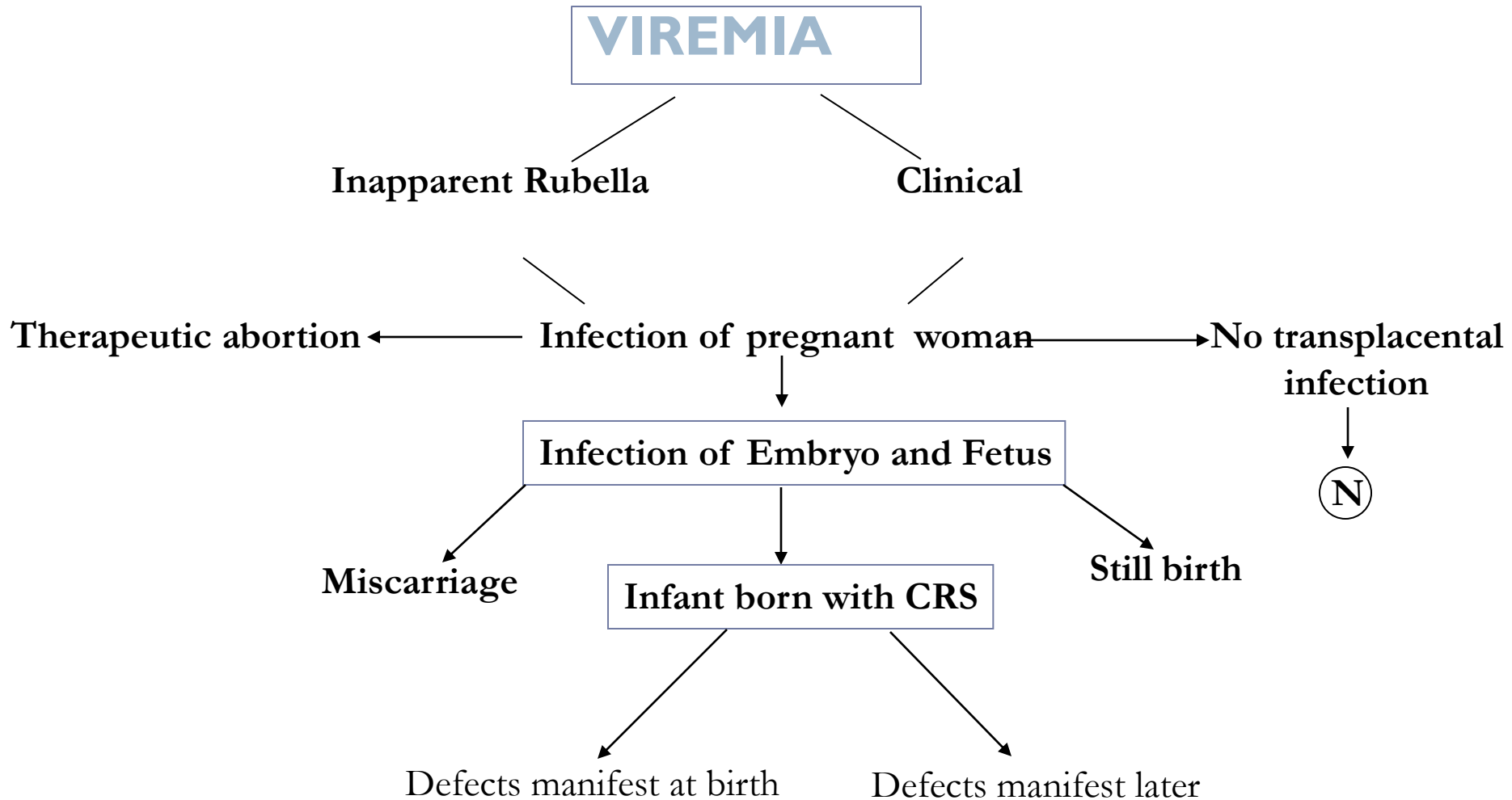
Congenital rubella syndrome

- ▶ Teratogenic property of the infection was documented by an Australian ophthalmologist Greeg in 1941
- ▶ Charachterized by classical triad of
 - cataracts,
 - cardiac disease
 - SNHL

MC isolated finding SNHL



TRANSMISSION IN UTERO




Fetal involvement as a function of gestation

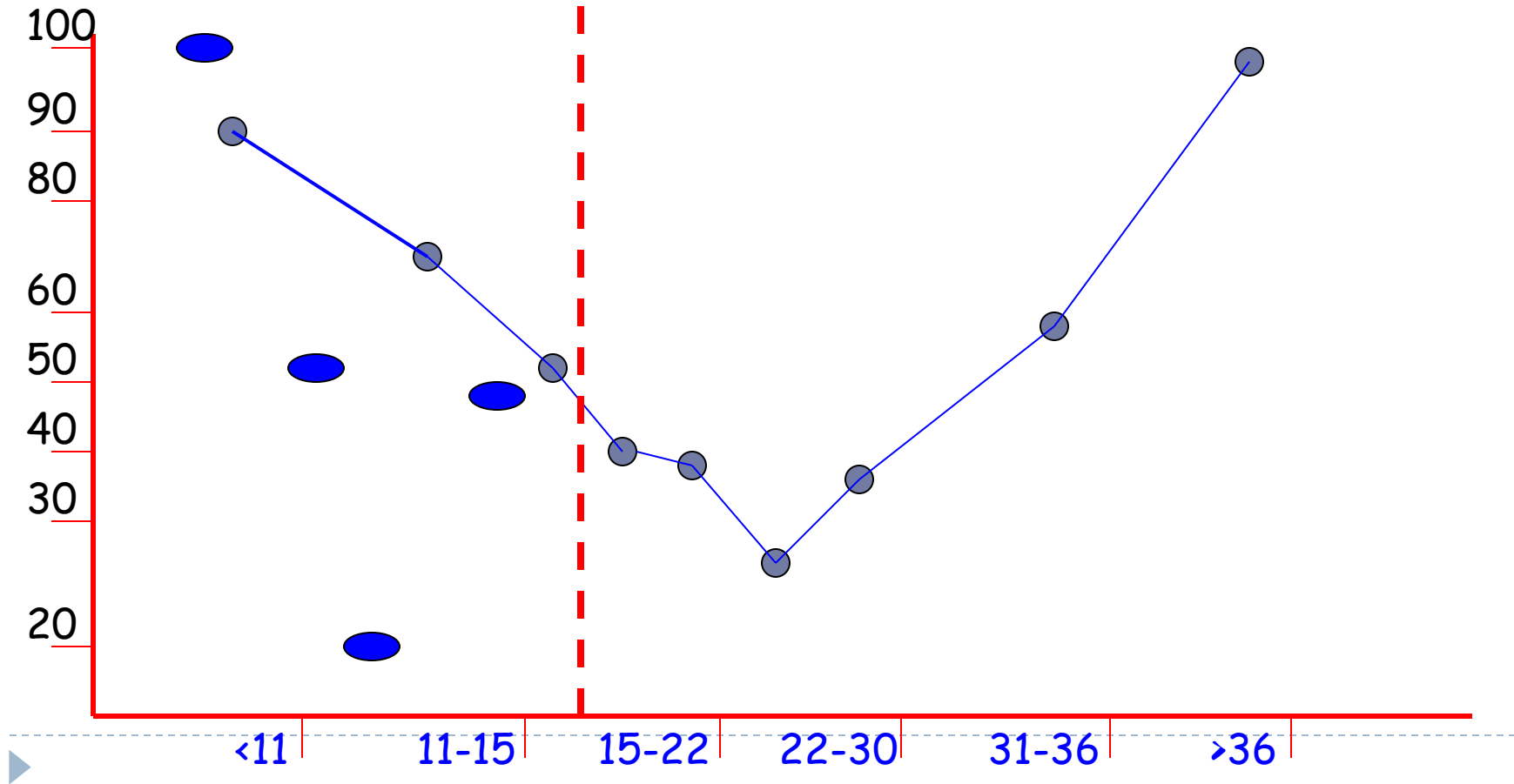
Maternal infection

- ▶ <12 wks [period of organogenesis]: **81 %** fetal infection , cardiac defects & deafness involvement
- ▶ 13-16 wks - 54%- retinopathy, hearing loss , CNS defects
- ▶ 17-22 wks -36%
- ▶ 23-30 wks- 30 %
- ▶ 31-36 wks -60%
- ▶ **>36 wks - 100%**





Transmission & risk of fetal infection




Manifestations: Three groups (Gregory et al): Transient

Reflect ongoing heavy viral infection

- Hepatosplenomegaly, hepatitis
Jaundice,
- Thrombocytopenia, blue-berry muffins
- Interstitial pneumonia,
- Hemolytic anemia
- Adenopathy, long bone growth defects
Large AF, cloudy cornea, diarrhoea

EXPANDED
RUBELLA
SYNDROME






Manifestations: Permanent

from defective organogenesis & tissue destruction

- Deafness - MC (80%)
- Salt & pepper retinopathy
- CHD(PDA,Pulm stenosis)
- CNS anomalies - microcephaly, mental & motor retardation, autism (6%)

CRS



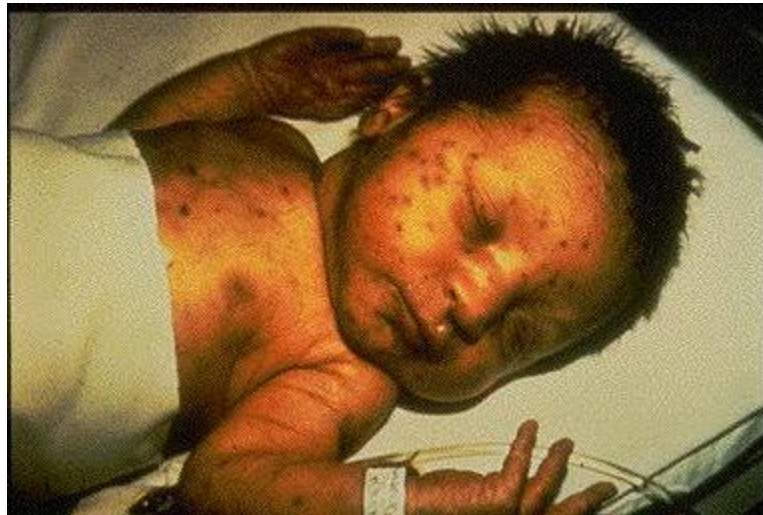

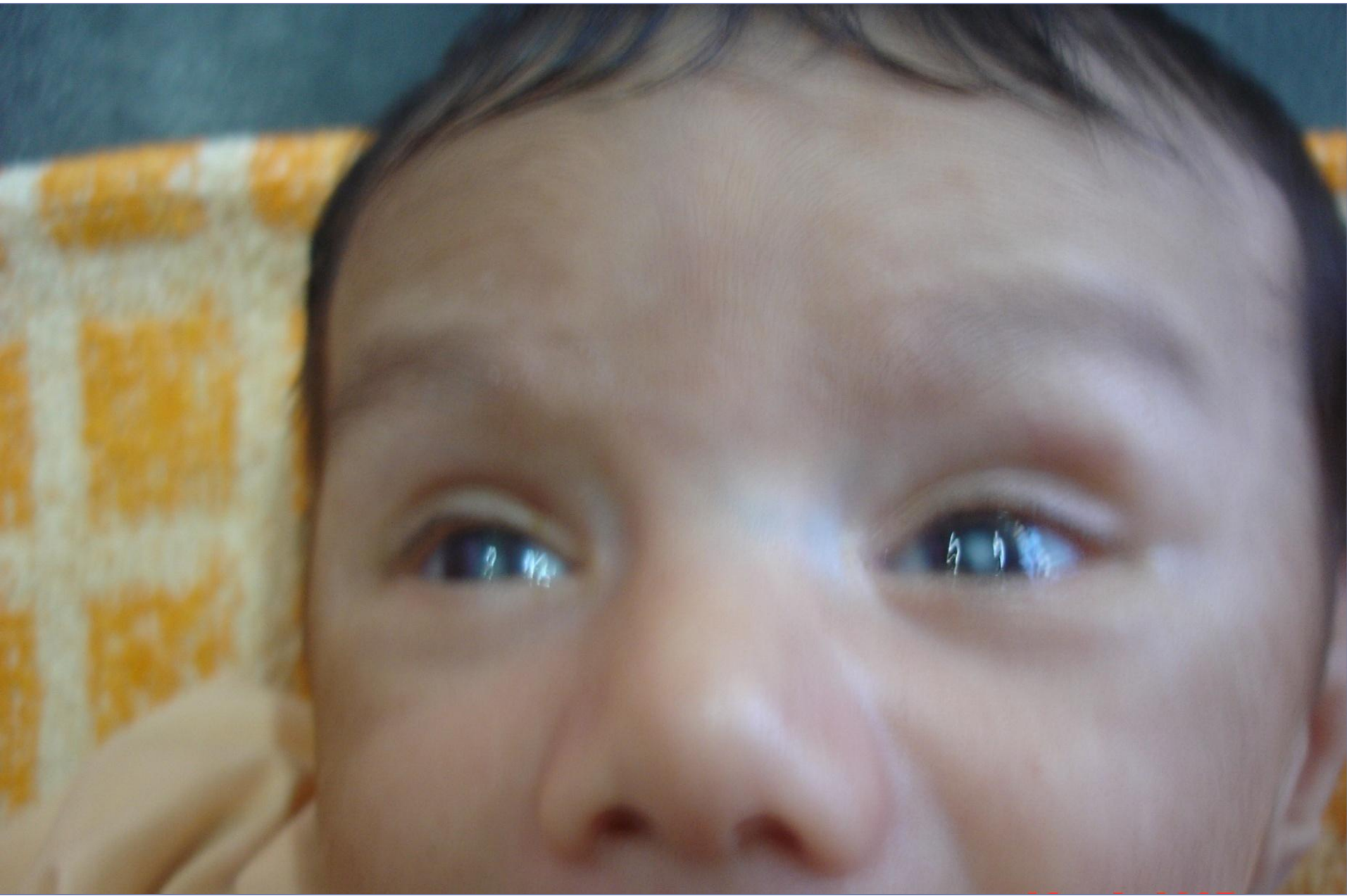
Manifestations : Developmental & late onset:

- - Endocrinopathies (IDDM -MC(20%)
Thyroid dysfunction (5%))
 - deafness, vascular effects
 - Progressive CNS disease,
 - ocular damage

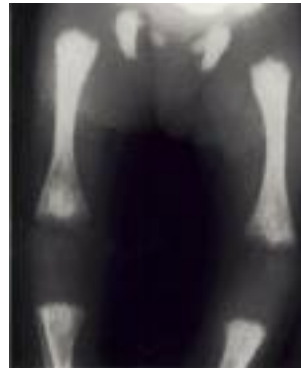

Congenital rubella- blue berry muffins





Metaphyseal lucencies



Diagnosis - maternal infection

- Clinical diagnosis - unreliable; lab. diagnosis is essential
- Techniques
 - a) Isolation - nose, throat
 - b) Serology - more realistic
- Acute primary infection -
 - 4 fold rise in the AB level (between acute & convalescent phase) (or)
 - Presence of rubella specific IgM



Diagnosis - Interpretation

- Rubella vaccine \geq 1 yr. age ----> immune; no risk
- Exposed & seropositive ----> Fetus not at risk
- Exposed & seronegative ----> serum 3-4 weeks after exposure ----> infected if positive ----> fetus at risk
- Exposed & uncertain ----> serum with in 7 days ----> positive ----> immune, no risk



Diagnosis - neonate

Guidelines:

- Any one of the following (to label as congenital rubella infection)
 - A) Isolation of virus
 - B) Rubella specific IgM - cord/neonatal serum
 - C) Persistent/rising IgG titers
- Above + congenital defects = CRS



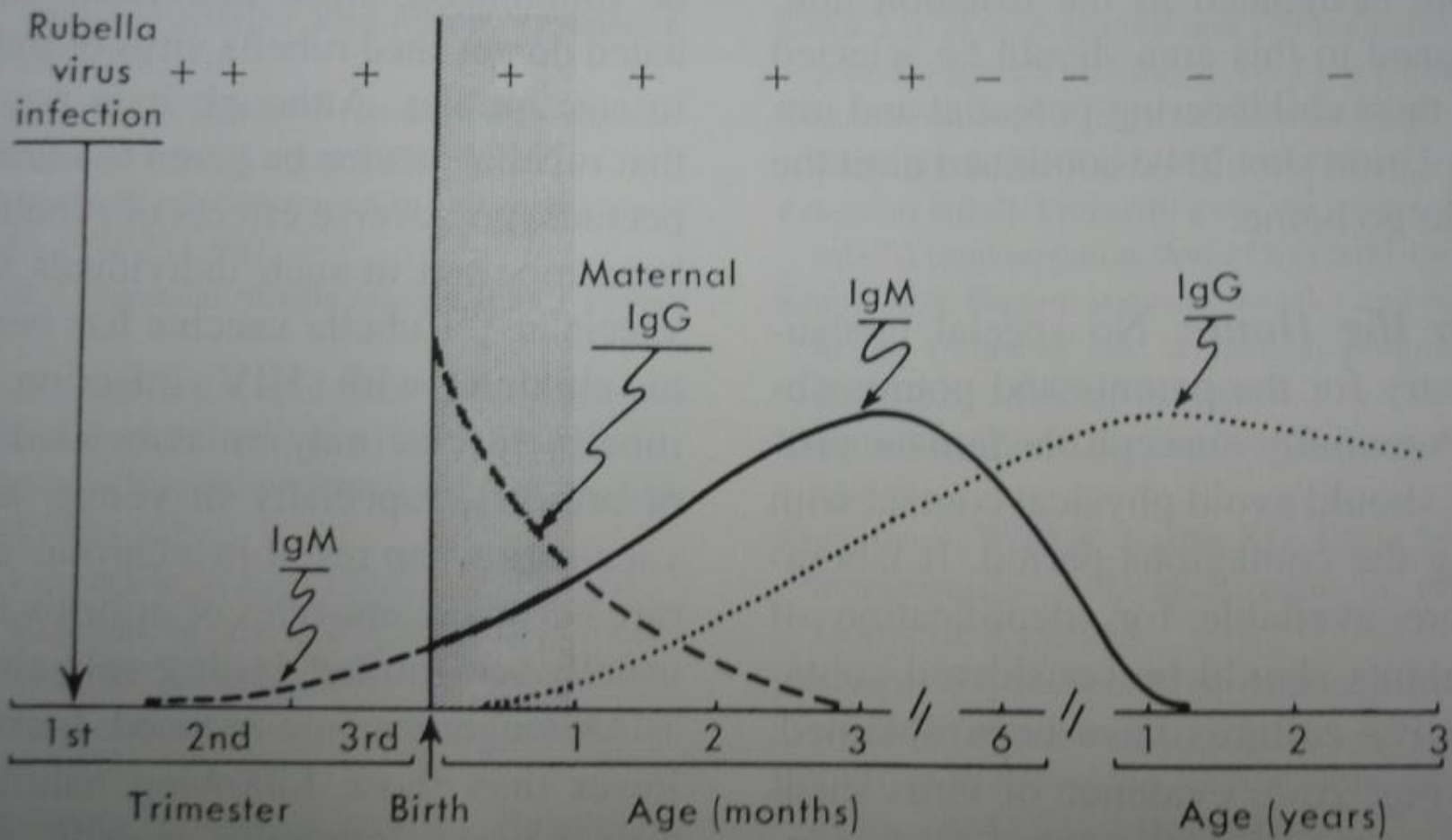
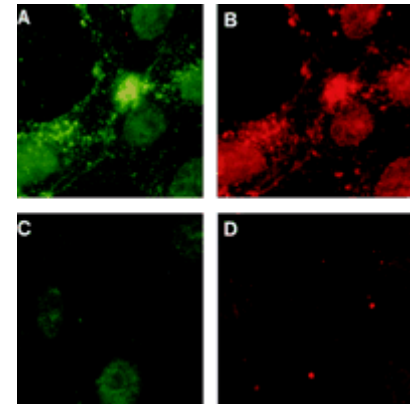


FIG. 26-6 Natural history of congenital rubella. Pattern of virus excretion and antibody response.

Isolation and Identification of virus

- ▶ Nasopharyngeal / throat swabs taken 6 days prior or after appearance of rash is a good source of Rubella virus
- ▶ Using cell culture antigens can be detected by immunofluorescent



Management

- ▶ Antenatal infection:
 - Counselling
 - Termination of pregnancy – infection before 20 wks


 - ▶ **Congenital infection:**
 - I/V/O Chronicity
 - Managed as a dynamic state rather than a static disease state
-



MGT. CONTD.

- ▶ Multidisciplinary approach
- ▶ Med, Surg, Edu, & rehabilitative
- ▶ Complete Ped, Cardiology, Neuro, Ophthal & Audiologic examn.
- ▶ complemented by CBC, Radiology & CSF evaluation in asymptomatic patients
- ▶ Hearing & Visual Aids, Contact lens, Occ. & Physio. therapy





Role of 'Ig'

Current recommendation:

- Pregnant women known to have been exposed to rubella, who do not want to terminate pregnancy under any circumstances - large doses (20ml) should be administered
- Patient should be advised - protection from fetal infection cannot be guaranteed

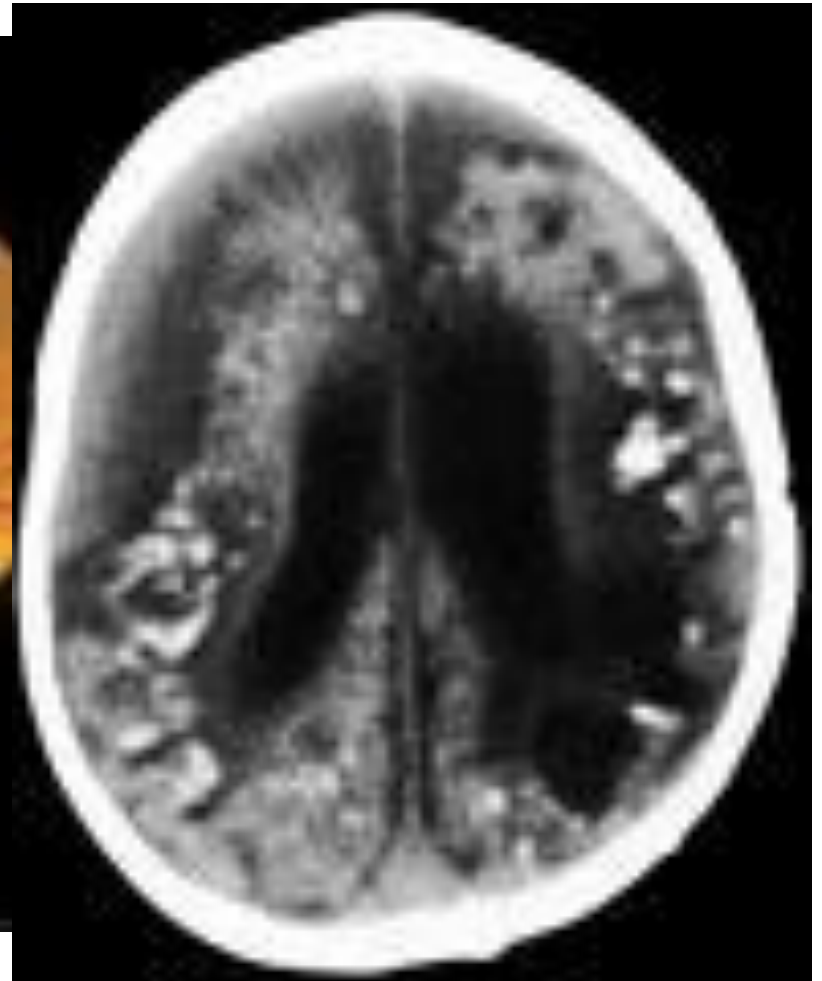
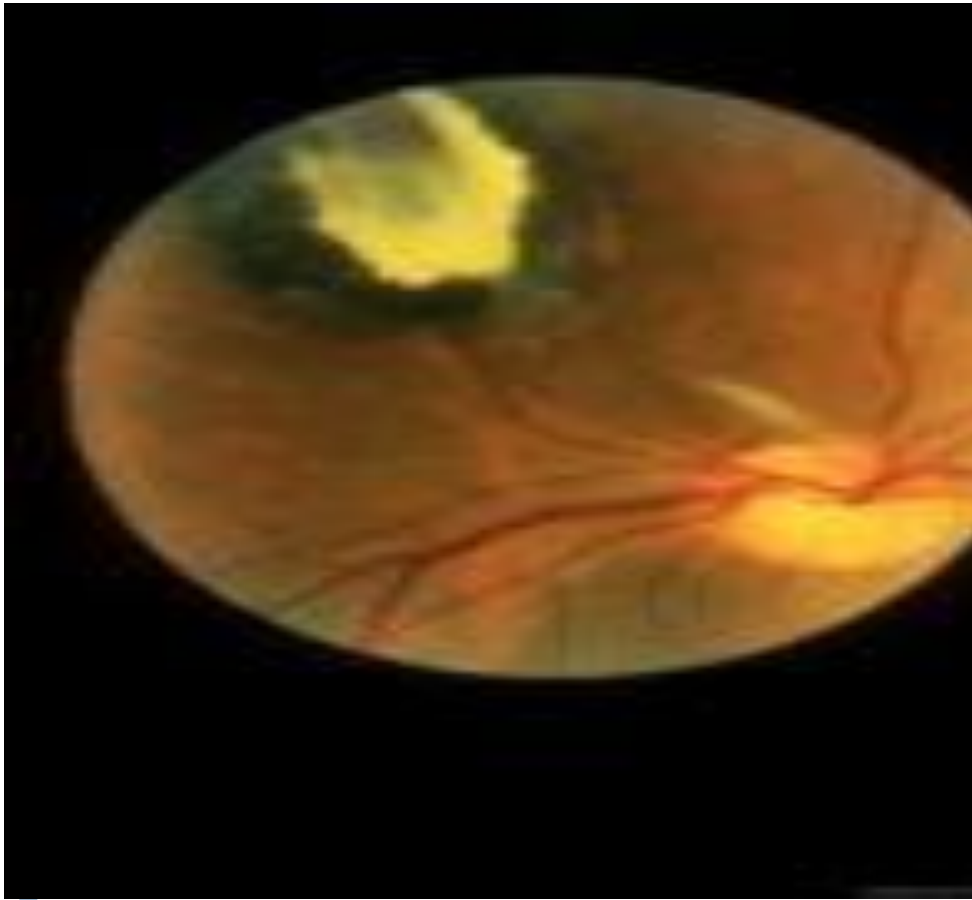


Prevention

- ▶ **Isolation key role in prevention of infection**
- ▶ **Infected patients can shed the virus even up to 12- 15 months of age & can be infective**
- ▶ **Vaccination two approaches---Childhood immunization with MMR vaccine at 15 months& post pubertal vaccination of adolescent girls**



Congenital toxoplasmosis



Congenital toxoplasmosis

- ▶ Classic triad – chorioretinitis, hydrocephalus, intracranial calcifications
- ▶ 85 % - asymptomatic at birth
- ▶ Pathogen
Toxoplasma gondii--obligate, intra cellular protozoan parasite, important pathogen for fetus, neonate & immunocompromized patient



Pathophysiology

- ▶ Cat- only definitive host- sheds millions of oocysts in the stool, for 2wks / more
- ▶ Children & adults- susceptible if not immune,
- ▶ Transmission by direct ingestion of oocysts, from uncooked meat
- ▶ Congenital infection- parasites from maternal circulation invade & multiply with in placental cells before reaching the fetus



Contd...

- ▶ Transmission from placenta to fetus - < 4wks to 16 wks
- ▶ Transmission rate - 1st trimester -15 %
 - 3rd trimester -60%
 - term – 90 %

Fetal disease severity – inversely proportional to gestational age

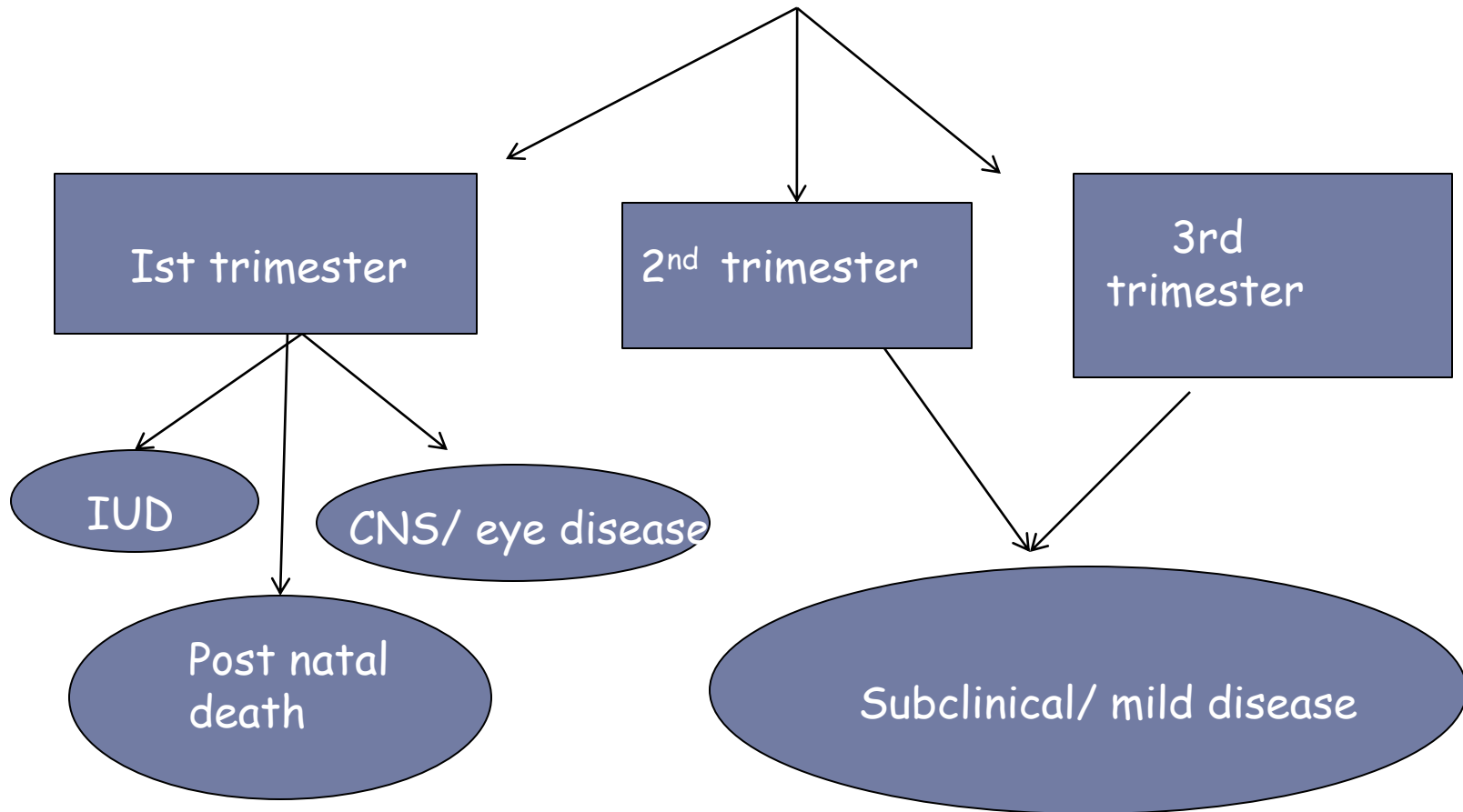


Outcome as a function of gestation

- ▶ Fetus infected in 1st trimester-die in utero/ neonatal period, or have severe CNS disease & eye involvement
- ▶ Fetuses infected in 2nd & 3rd trimester: mild / sub clinical disease in newborn period.
- ▶ Congenital infections after -Maternal chronic infections are rare, can occur when mother is HIV infected

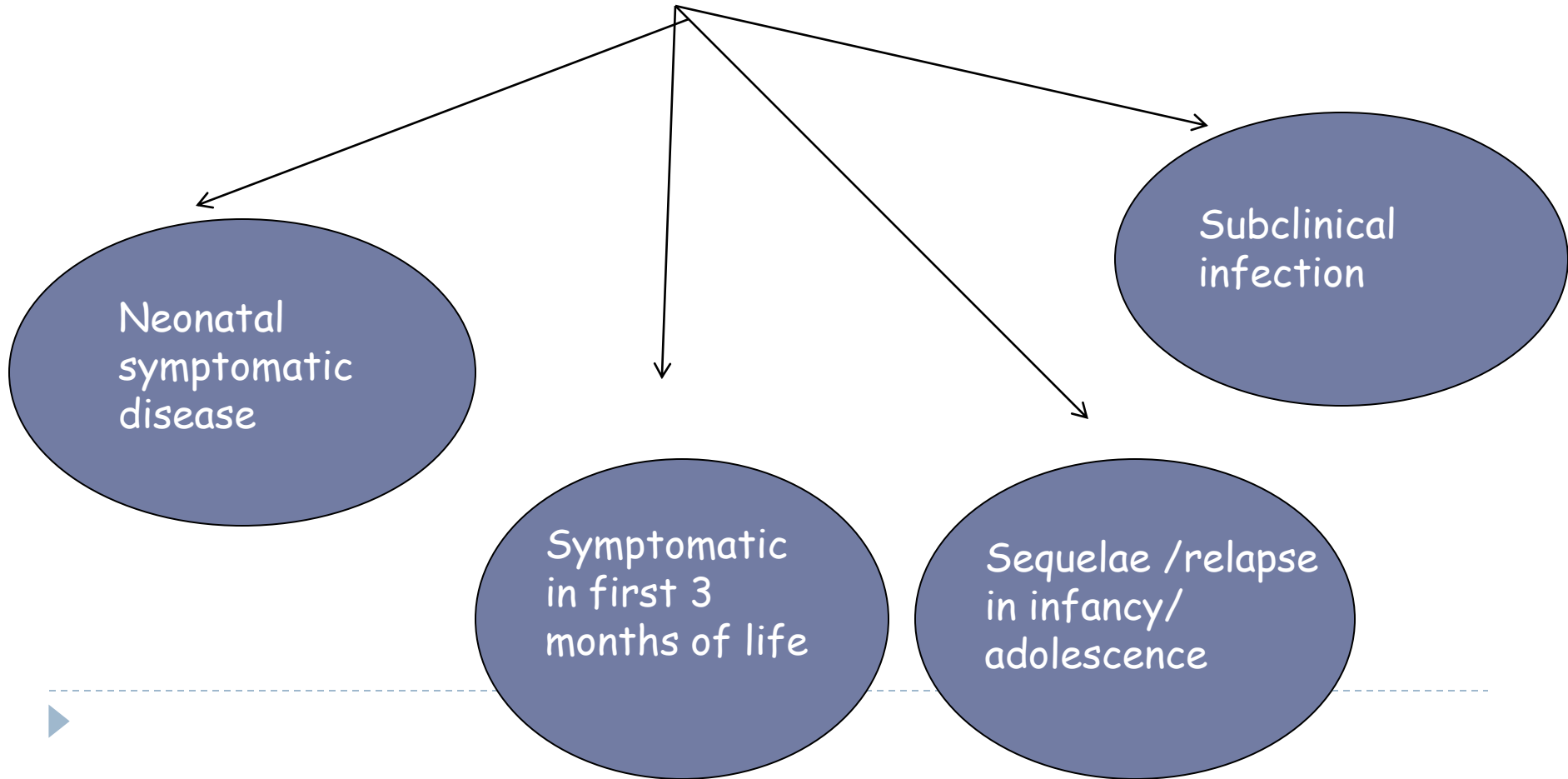


Outcome Vs gestation



Toxoplasma clinical diagnosis

Four recognized patterns



Specific clinical manifestations

- ▶ Neurologic-microcephaly/ hydrocephalus, seizures, opisthotonus, paralysis, swallowing difficulties, deafness, encephalitis, intra cranial calcifications, endocrine dysfunction
- ▶ Ophthalmologic-
 - ▶ MC cause for chorioretinitis & visual impairment
 - ▶ Focal necrotizing retinitis- usually bilateral, yellow white cotton wool patches
 - ▶ macular involvement- macular scars



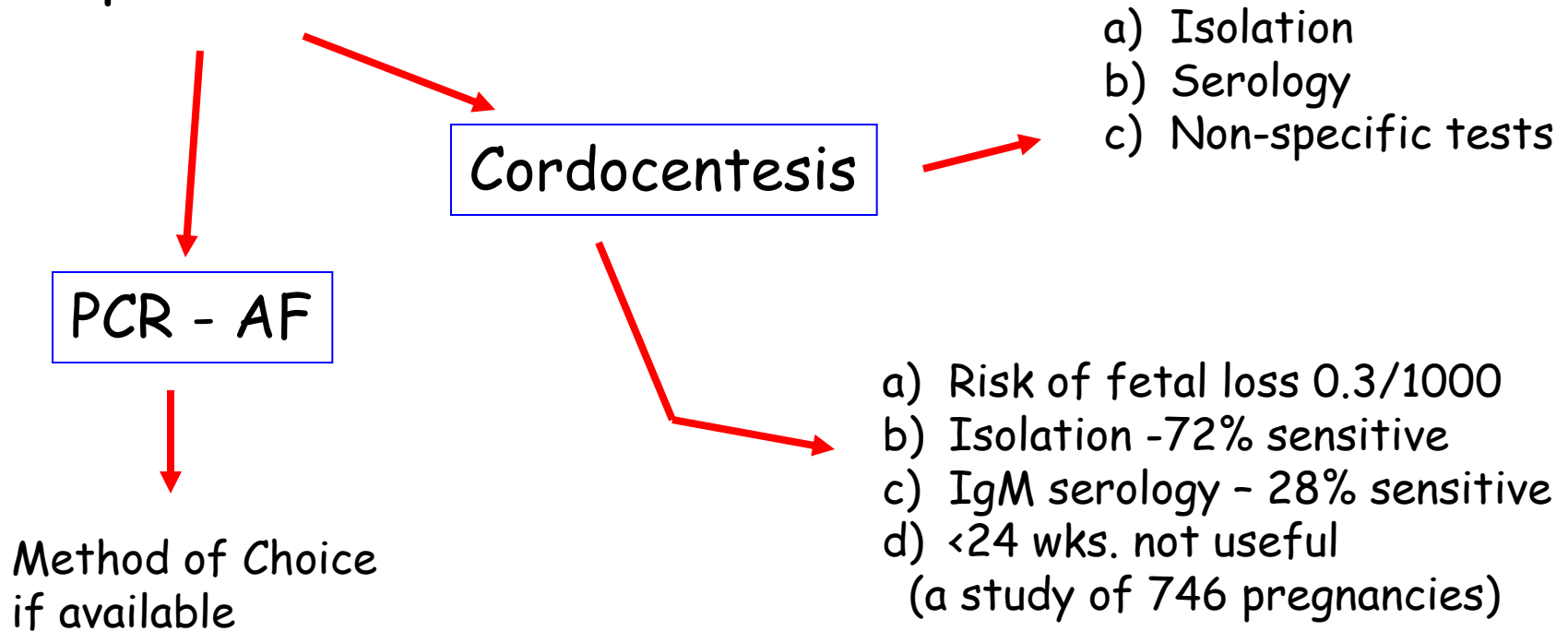
Diagnosis - newborn

- Serology:
 - A) Investigation of choice - IgM assay in the cord or neonatal serum
 - B) Method of choice - ISAGA (acceptable-IgM DS-capture ELISA)
 - IgA anti P30 antibodies by ELISA : Encouraging
 - IgE ELISA - upcoming modality



Prenatal diagnosis

- Options



Guidelines for evaluation

- A) History & physical examination
- B) Ophthalmology & neurological assessment
- C) CBC, LFT, G6PD assessment, cranial CT
- D) CSF - cytology, biochem, IgG & IgM AB
- E) Serological tests, isolation
- F) ABER



Contd...

- ▶ Ig G Avidity testing : differentiates acute Vs remote infection
- ▶ PCR – can detect Toxoplasma in peripheral blood buffy coat, CSF & amniotic fluid
- ▶ sensitivity is >90% -between 17-21 wks gestation
- ▶ 50-60%- after 21 wks



Other diagnostic testing

- ▶ PBC- leukocytosis/ leukopenia, lymphocytopenia, monocytosis, eosinophilia [>30%] & thrombocytopenia
- ▶ LFT& Renal function tests
- ▶ G6pd screen- before starting sulfadiazine
- ▶ Quantitative Igs
- ▶ CSF analysis



Contd...

- ▶ BERA-
- ▶ CT head [plain]: calcifications scattered in white matter, basal ganglia, periventricular, Hydrocephalus: periaqueductal obstruction, Cortical atrophy & porencephalic cysts
- ▶ Acute toxoplasmosis- tachyzoites
- ▶ Acute & Chronic toxoplasmosis-cysts in tissues & body fluids
- ▶ Tissue / mouse culture:from peripheral blood buffy coat/ placenta- takes 1- 6 wks



Management Of mother & infant

- ▶ **Mother: spiramycin- before 18 wks- till term, If fetus is not infected by 18 wk (AF PCR)**
- ▶ Sulfadiazine alone : Fetal infections before 17 wks
- ▶ **Pyrimethamine,sulfadiazine& folinic acid-**
 - ▶ Confirmed fetal infections after 18 wks
 - ▶ Amniocentesis couldnot be performed
 - ▶ All acute maternal infections after 24 wk



Management

- ▶ In all acute infections during pregnancy – amniotic fluid PCR should be performed
- ▶ Ultrasonographic monitoring of ventricular size is also important



Contd...

- ▶ Therapeutic abortion & patient education
- ▶ Neonatal management-therapy is recommended regardless of symptoms
 - ▶ To prevent sequele
 - ▶ To resolve acute symptoms
 - ▶ To improve outcomes
 - ▶ Drugs act against tachyzoites only—so extended therapy –up to 1 yr



Neonatal management

- ▶ Pyrimethamine-
 - first 2 days- 1mg/kg, 12th hrly
 - 2-6 months- 1mg/kg/day
 - Till 1yr-1mg/kg thrice weekly
 - symptom resolution – first few weeks
- ▶ Prednisone- 0.5mg/kg/dose, 12th hrly
 - active CNS disease & active chorioretinitis, till acute symptoms resolve

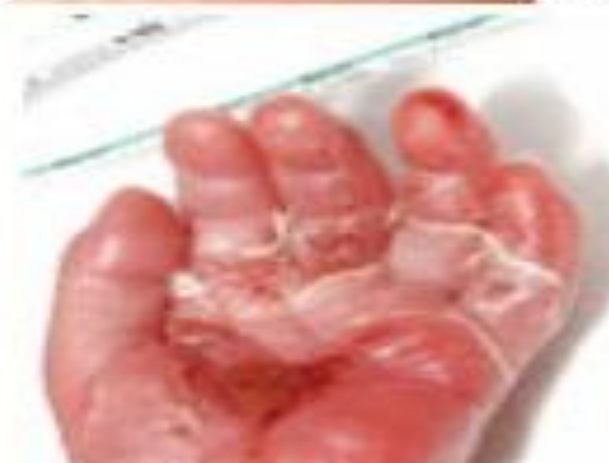
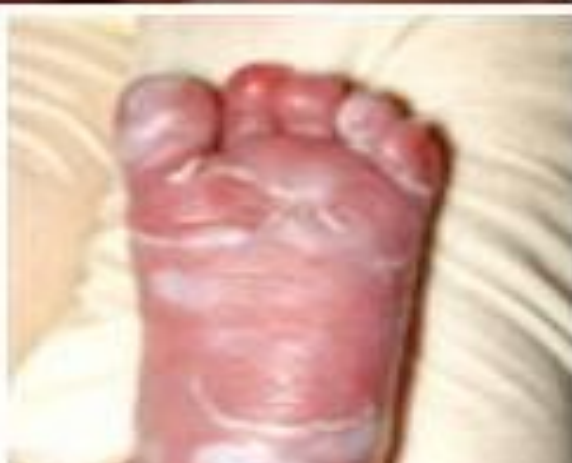
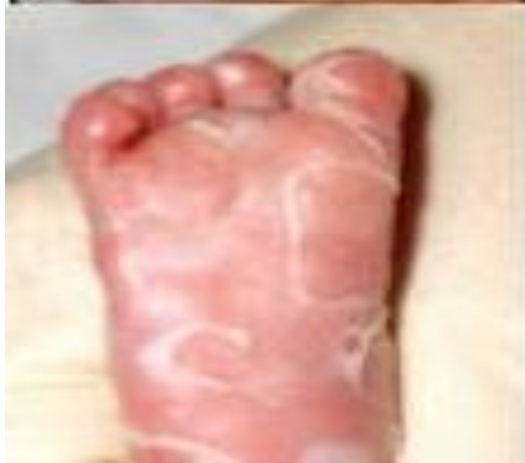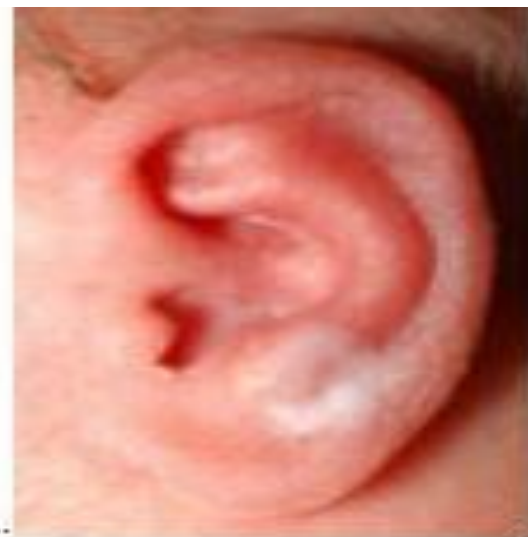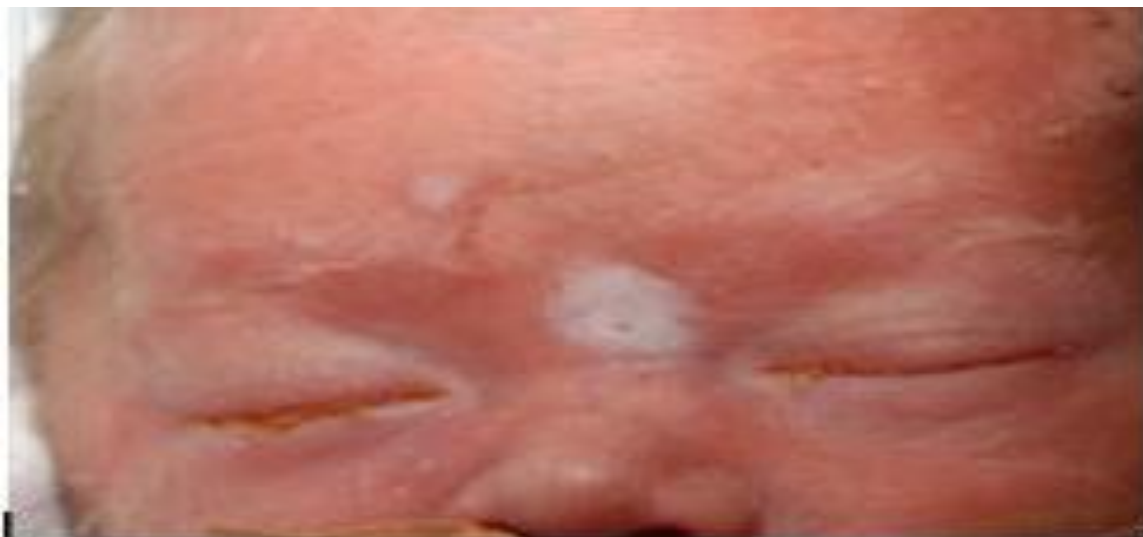Contd...

- ▶ Ventricular shunting- for hydrocephalus
- ▶ Multidisciplinary approach
- ▶ Co-existing HIV infection—treat similarly, add anti retro viral drugs, watch for bone marrow toxicity



Thank you



MCQs

- ▶ **Which of the following confer(s) passive immunity:**
- ▶ Hepatitis B vaccine
- ▶ MMR vaccine
- ▶ Hepatitis B immunoglobulin
- ▶ Infection with measles virus



▶ **Immunoglobulins are made:**



- ▶ In a laboratory from deactivated viruses and bacteria
- ▶ From the plasma of a person in the acute phase of an infectious Disease
- ▶ From the pooled plasma of blood donors
- ▶ From protein produced artificially in a laboratory



▶ **The most suitable site for intramuscular vaccination is:**

- ▶ Anterolateral aspect of the thigh
- ▶ Deltoid area of the upper arm
- ▶ Fatty area of buttock
- ▶ Anywhere in buttock

