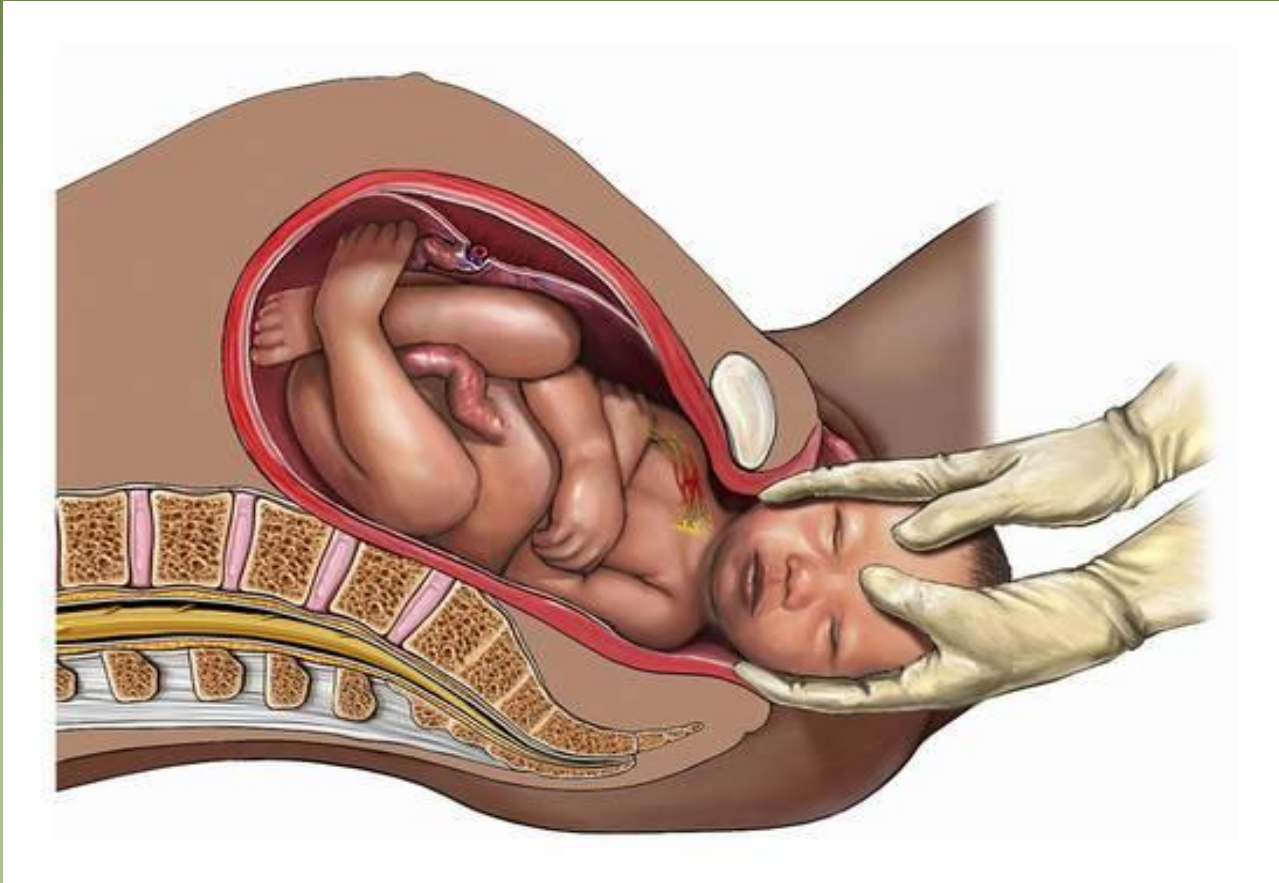


# ***NORMAL LABOR***



**DR. RAKHI GAUR  
AIIMS RISHIKESH**

# INTRODUCTION

Labor is characterized by the presence of regular uterine contractions with effacement and dilatation of the cervix and fetal descent. A parturient is a patient in labor and parturition is the process of giving birth. Delivery is the expulsion or extraction of a viable fetus out of the womb. It is not synonymous with labor; delivery can take place without labor as in elective cesarean section. Delivery may be vaginal, either spontaneous or aided, or it may be abdominal.

# DEFINITION

- ❖ Series of events that take place in the genital organs in an effort to expel the viable products of conception (fetus, placenta and the membranes) out of the womb through the vagina into the outer world is called Labor.
- ❖ It may occur prior to 37 completed weeks, when it is called the preterm labor. Expulsion of a previable live fetus occurs through the same process but in a miniature form and is called mini-labor.

# CRITERIA OF NORMAL LABOR

## NORMAL LABOR (EUTOCIA):

Labor is called normal if it fulfills the following criteria.

- (1) Spontaneous in onset and at term.
- (2) With vertex presentation.
- (3) Without undue prolongation.
- (4) Natural termination with minimal aids.
- (5) Without having any complications affecting the health of the mother and/or the baby.

# CRITERIA OF ABNORMAL LABOUR

**ABNORMAL LABOR (DYSTOCIA):** Any deviation from the definition of normal labor is called Abnormal labor. Thus, labor in a case with presentation other than vertex or having some complications even with vertex presentation affecting the course of labor or modifying the nature of termination or adversely affecting the maternal and/or fetal prognosis is called abnormal labor.

# CAUSES OF ONSET OF LABOR

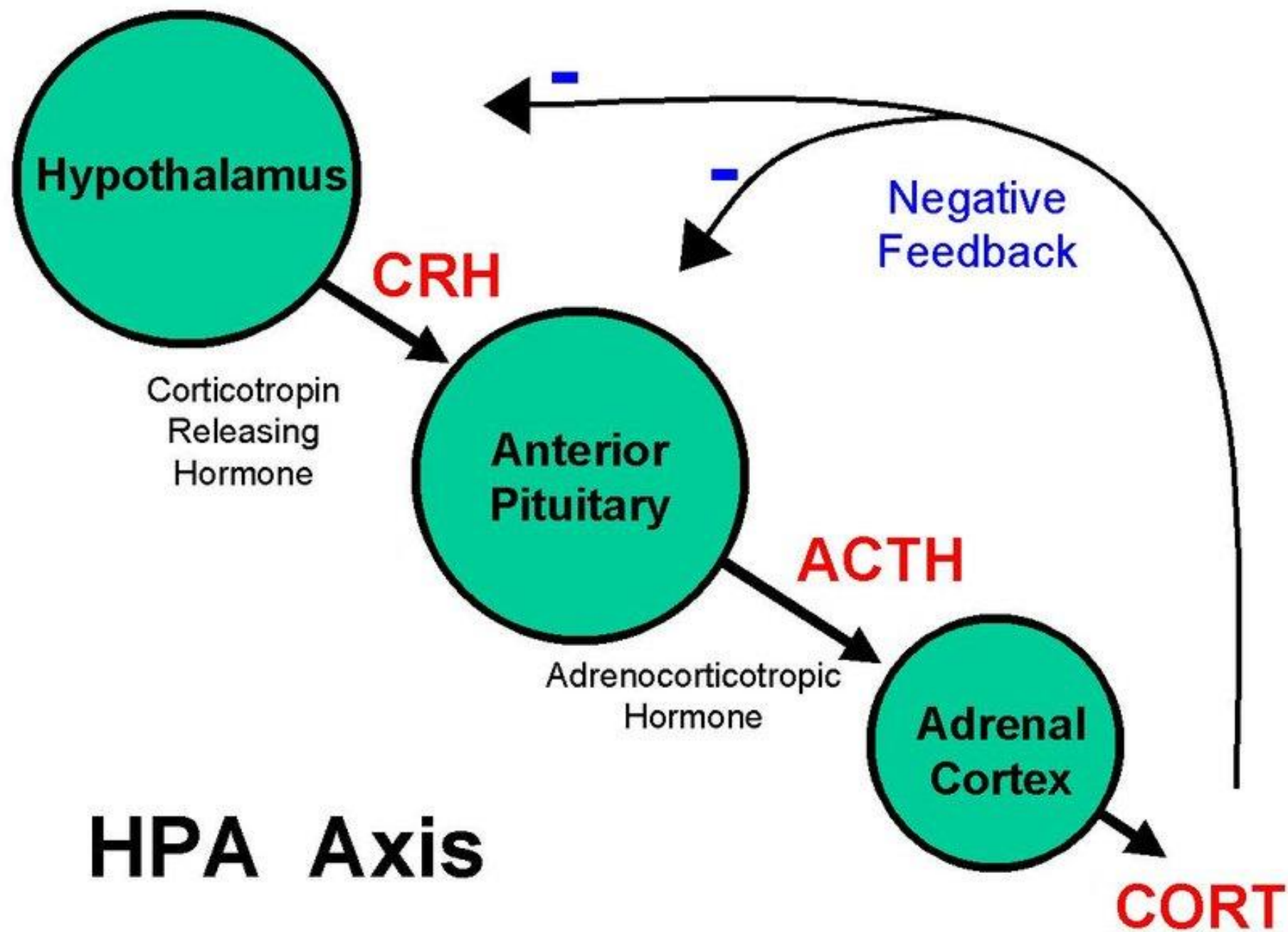
The precise mechanism of initiation of human labor is still obscure. Endocrine, biochemical and mechanical stretch pathways as obtained from animal experiments, however, put forth the following hypotheses.

1. Uterine distension: Stretching effect on the myometrium by the growing fetus and liquor amnii can explain the onset of labor at least in twins or polyhydramnios.



# Cont...

2. Fetoplacental contribution: Cascade of events activate fetal hypothalamic-pituitary-adrenal axis prior to onset of labor → increased CRH → increased release of ACTH → fetal adrenals → increased cortisol secretion → accelerated production of estrogen and prostaglandins from the placenta.





# Cont...

3. Estrogen: The probable mechanisms are:

- Increases the release of oxytocin from maternal pituitary.
- Promotes the synthesis of myometrial receptors for oxytocin and prostaglandins.
- Increases the excitability of the myometrial cell membranes.

4. Progesterone: Cortisol inhibits the conversion of fetal pregnenolone to progesterone. Progesterone levels therefore fall before labor. It is the alteration in the estrogen : progesterone ratio.

# Cont...

5. Prostaglandins: Prostaglandins are the important factors, which initiate and maintain labor. The major sites of synthesis of prostaglandins are—amnion, chorion, decidual cells and myometrium.

Synthesis is triggered by—rise in estrogen level, glucocorticoids, mechanical stretching in late pregnancy, increase in cytokines (IL-1, 6, TNF), infection, vaginal examination, and separation or rupture of the membranes. The prostaglandin synthesis reaches a peak during the birth of placenta probably contributing to its expulsion and to the control of postpartum hemorrhage.

# Cont....

## 6. Oxytocin and myometrial oxytocin receptors:

(i) Large number of oxytocin receptors are present in the fundus compared to the lower segment and the cervix. (ii) Receptor number increases during pregnancy reaching maximum during labor. (iii) Receptor sensitivity increases during labor. (iv) Oxytocin stimulate synthesis and release of PGs ( $E_2$  and  $F_{2\alpha}$ ) from amnion and decidua. Vaginal examination and amniotomy cause rise in maternal plasma oxytocin level (Ferguson reflex). Fetal plasma oxytocin level is found increased during spontaneous labor compared to that of mother. Its role in human labor is not yet established.

# WHAT IS FALSE LABOUR

**FALSE PAIN:** (Synonym: false labor, spurious labor): It is found more in primigravidae than in parous women. It usually appears prior to the onset of true labor pain by 1 or 2 weeks in primigravidae and by a few days in multiparae. Such pains are probably due to stretching of the cervix and lower uterine segment.

False labor pain is: (i) Dull in nature, (ii) confined to lower abdomen and groin, (iii) not associated with hardening of the uterus, (iv) they have no other features of true labor pain and (v) usually relieved by enema or sedative.

# SIGNS OF PRELABOUR

**PRELABOR:** (Synonym: premonitory stage): The premonitory stage may begin 2–3 weeks before the onset of true labor in primigravidae and a few days before in multiparae. The features are inconsistent and may consist of the following:

- ☐ **Cervical changes:** A few days prior to the onset of labor, cervix becomes ripe. A ripe cervix is (a) soft, (b) 80% effaced (<1.5 cm in length), (c) admits one finger easily, and (d) cervical canal is dilatable.
- ☐ **Appearance of false pain**

# Cont...

- ❑ “Lightening”: A few weeks prior to the onset of labor especially in primigravidae, the presenting part sinks into the true pelvis. It is due to active pulling up of the lower pole of the uterus around the presenting part. It signifies incorporation of the lower uterine segment into the wall of the uterus. This diminishes the fundal height and hence minimizes the pressure on the diaphragm. The mother experiences a sense of relief from the mechanical cardiorespiratory embarrassment. There may be frequency of micturition or constipation due to mechanical factor—pressure by the engaged presenting part. It is a welcome sign as it rules out cephalopelvic disproportion and other conditions preventing the head from entering the pelvic inlet.



# TRUE LABOUR PAIN

True labor pain is characterized by:

- (i) Painful uterine contractions at regular intervals,
- (ii) frequency of contractions increase gradually,
- (iii) intensity and duration of contractions increase progressively,
- (iv) associated with “show”,
- (v) progressive effacement and dilatation of the cervix,
- (vi) descent of the presenting part,
- (vii) formation of the “bag of forewaters” and
- (viii) not relieved by enema or sedatives.

# Cont...

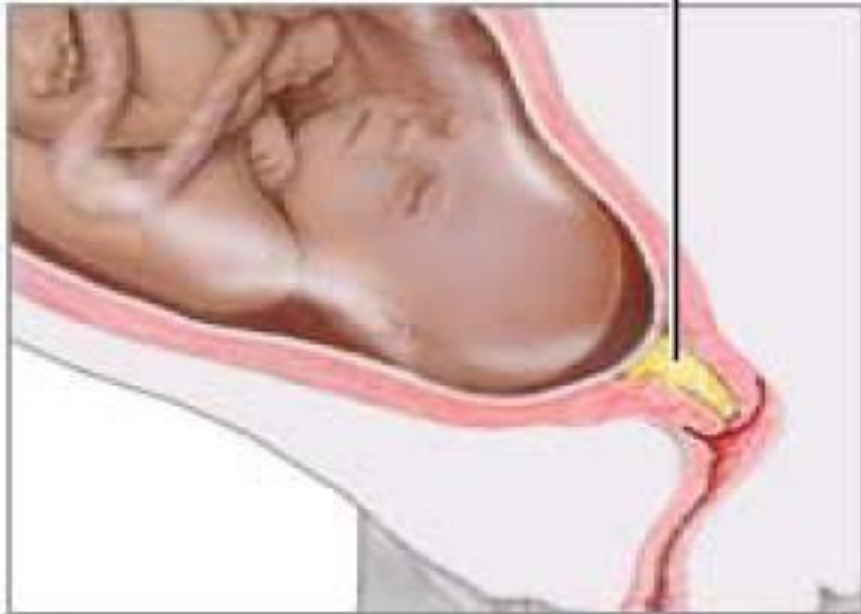
1.Labor pain: Throughout pregnancy, painless Braxton Hicks contractions with simultaneous hardening of the uterus occur. These contractions change their character, become more powerful, intermittent and are associated with pain. Pain more often felt in front of the abdomen or radiating toward the thighs.

# Cont...

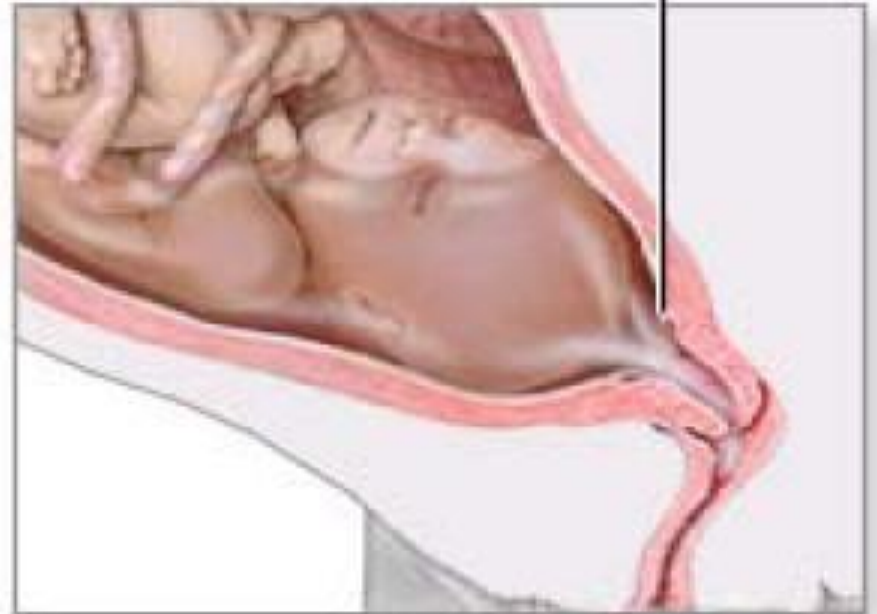
2.Show: With the onset of labor, there is profuse cervical secretion. Simultaneously, there is slight oozing of blood from rupture of capillary vessels of the cervix and from the raw decidual surface caused by separation of the membranes due to stretching of the lower uterine segment. Expulsion of cervical mucus plug mixed with blood is called “show”.

3.Dilatation of internal os: With the onset of labor pain, the cervical canal begins to dilate more in the upper part than in the lower, the former being accompanied by corresponding stretching of the lower uterine segment.

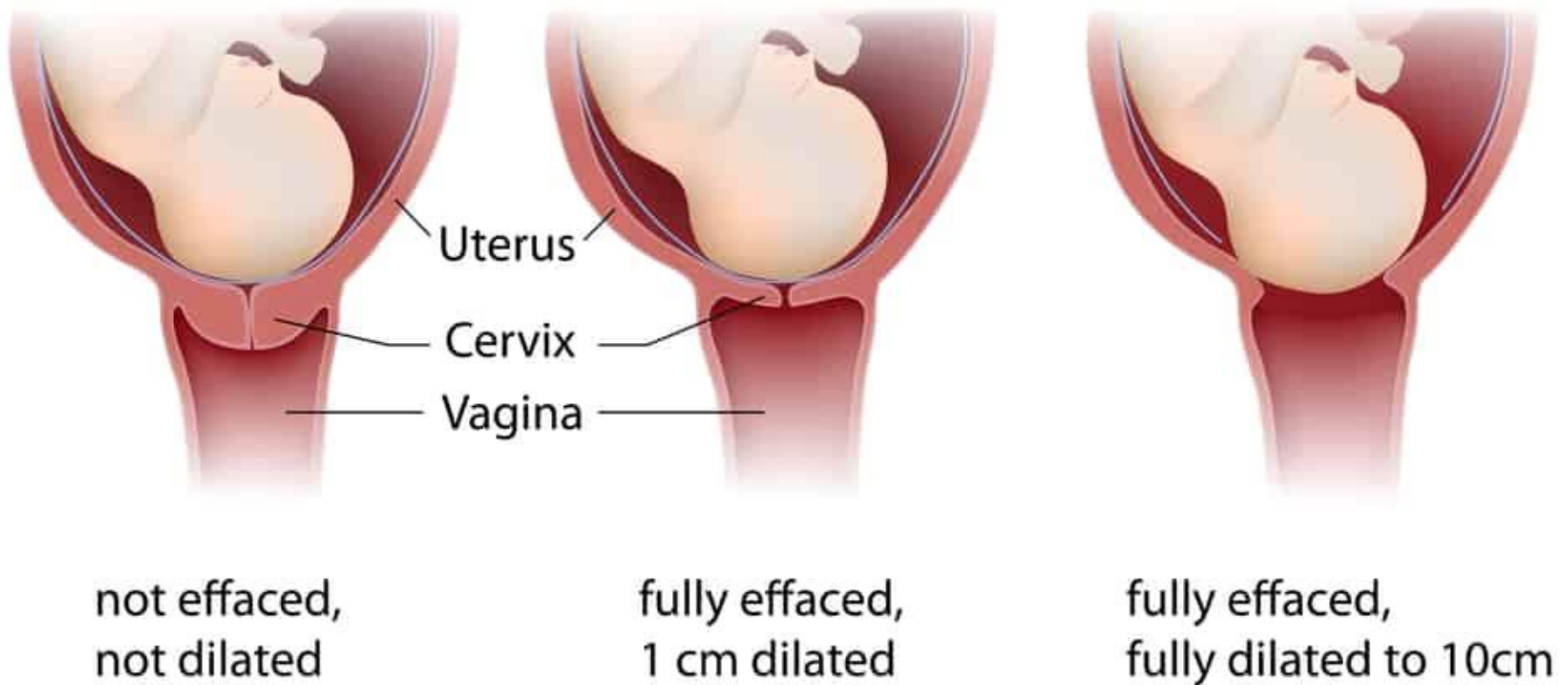
Mucus plug



Ruptured amnionic sac



# Cervical Effacement and Dilatation

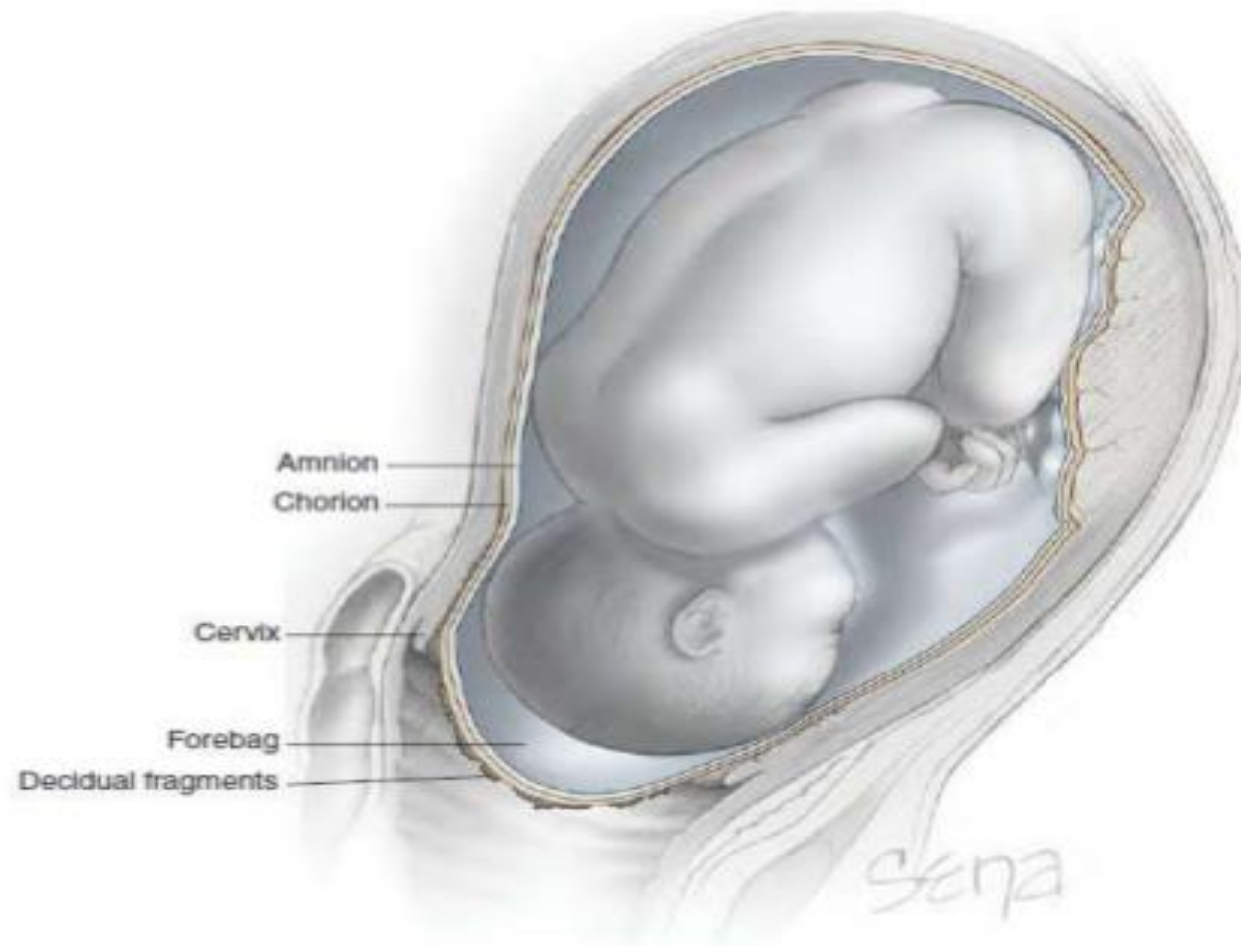


# Cont...

4. Formation of “bag of waters”: Due to stretching of the lower uterine segment, the membranes are detached easily because of its loose attachment to the poorly formed decidua. With the dilatation of the cervical canal, the lower pole of the fetal membranes becomes unsupported and tends to bulge into the cervical canal. As it contains liquor, which has passed below the presenting part, it is called “bag of waters”. During uterine contraction with consequent rise of intra-amniotic pressure, this bag becomes tense and convex. After the contractions pass off, the bulging may disappear completely. This is almost a certain sign of onset of labor.



# BAG OF MEMBRANES



# STAGES OF LABOR

Conventionally, events of labor are divided into three stages:

- First stage: It starts from the onset of true labor pain and ends with full dilatation of the cervix. It is, in other words, the “cervical stage” of labor. Its average duration is 12 hours in primigravidae and 6 hours in multiparae.
- Second stage: It starts from the full dilatation of the cervix (not from the rupture of the membranes) and ends with expulsion of the fetus from the birth canal. It has got two phases—
  - (1) The propulsive phase—starts from full dilatation up to the descent of the presenting part to the pelvic floor.
  - (2) The expulsive phase is distinguished by maternal bearing down efforts and ends with delivery of the baby. Its average duration is 2 hours in primigravidae and 30 minutes in multiparae.

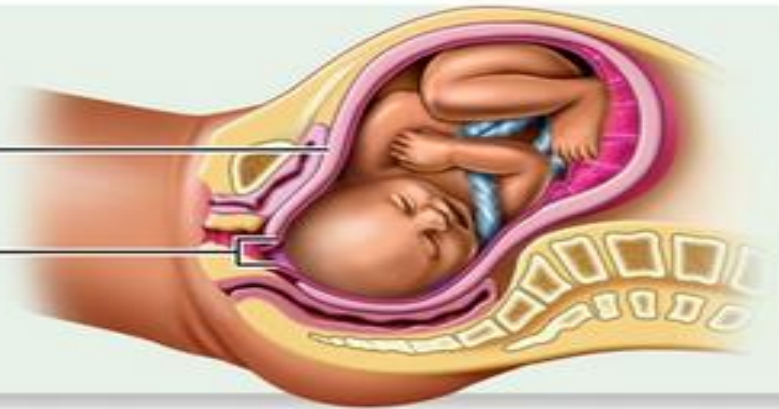# Cont...

- Third stage: It begins after expulsion of the fetus and ends with expulsion of the placenta and membranes (afterbirths). Its average duration is about 15 minutes in both primigravidae and multiparae. The duration is, however, reduced to 5 minutes in active management.
- Fourth stage: It is the stage of observation for at least 1 hour after expulsion of the afterbirths. During this period maternal vitals, uterine retraction and any vaginal bleeding are monitored. Baby is examined. These are done to ensure that both the mother and baby are well.

**Stage 1:**  
The cervix relaxes,  
causing it to dilate  
and thin out.

Uterus

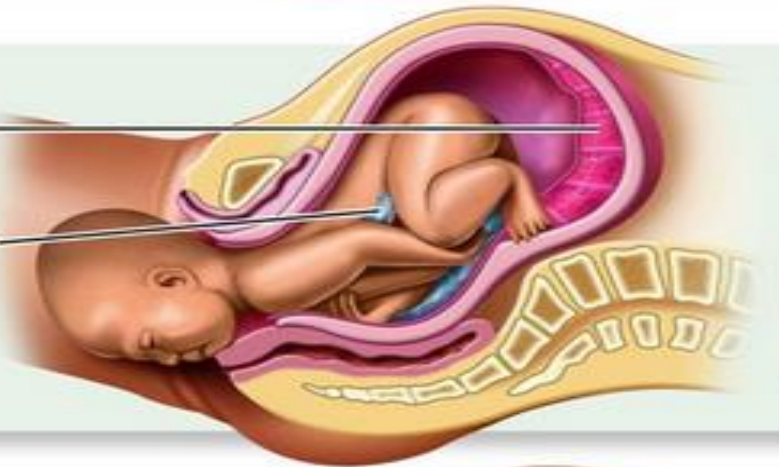
Cervix



**Stage 2:**  
Uterine contractions  
increase in strength  
and the infant is  
delivered.

Placenta

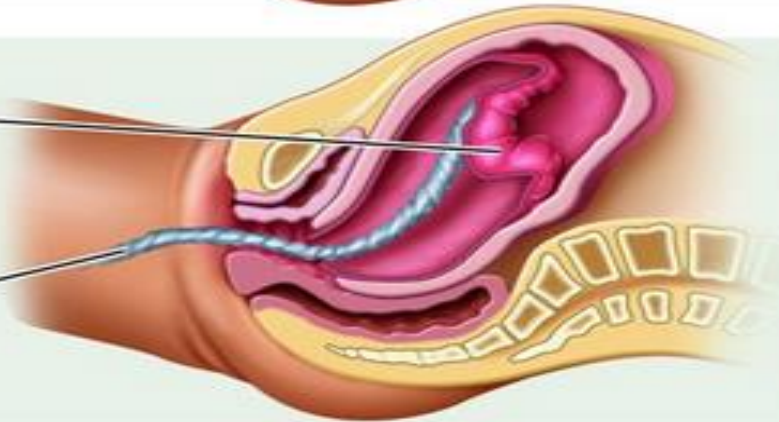
Umbilical  
cord



**Stage 3:**  
The placenta  
is expelled.

Placenta  
(detaching  
from uterus)

Umbilical  
cord





# PHYSIOLOGY OF NORMAL LABOR

During pregnancy there is marked hypertrophy and hyperplasia of the uterine muscle and the enlargement of the uterus. At term, the length of the uterus measures about 35 cm including cervix. The fundus is wider both transversely and anteroposteriorly than the lower segment. The uterus assumes pyriform or ovoid shape.

**UTERINE CONTRACTION IN LABOR:** Throughout pregnancy there is irregular involuntary spasmodic uterine contractions which are painless (Braxton Hicks) and have no effect on dilatation of the cervix. The character of the contractions changes with the onset of labor. While there are wide variations in frequency, intensity and duration of contractions, they remain usually within normal limits in the following patterns.

# Cont...

- ❑ There is good synchronization of the contraction waves from both halves of the uterus and also between upper and lower uterine segments.
- ❑ There is fundal dominance of contractions that diminish gradually in duration through midzone down to lower segment.
- ❑ The waves of contraction follow a regular pattern.
- ❑ The upper segment of the uterus contracts more strongly and for a longer time than the lower part.
- ❑ Intra-amniotic pressure rises beyond 20 mm Hg during uterine contraction.
- ❑ Good relaxation occurs in between contractions to bring down the intra-amniotic pressure to less than 8 mm Hg.



# Cont...

During contraction, uterus becomes hard and somewhat pushed anteriorly. Simultaneously, the patient experiences pain which is situated more on the hypogastric region, often radiating to the thighs. Probable causes of pain are:

- (a) Myometrial hypoxia during contractions (as in angina),
- (b) stretching of the peritoneum over the fundus,
- (c) stretching of the cervix during dilatation,
- (d) stretching of the ligaments surrounding the uterus
- (e) compression of the nerve ganglion.

# Cont...

- Intensity: The intensity of uterine contraction describes the degree of uterine systole. The intensity gradually increases with advancement of labor until it becomes maximum in the second stage during delivery of the baby. Intrauterine pressure is raised to 40–50 mm Hg during first stage and about 100–120 mm Hg in second stage of labor during contractions. In spite of diminished pain in third stage, the intrauterine pressure is probably the same as that in the second stage. The diminished pain is due to lack of stretching effect.

# Cont...

- ❑ **Duration:** In the first stage, the contractions last for about 30 seconds initially but gradually increase in duration with the progress of labor. Thus in the second stage, the contractions last longer than in the first stage.
- ❑ **Frequency:** In the early stage of labor, the contractions come at intervals of 10–15 minutes. The intervals gradually shorten with advancement of labor until in the second stage, when it comes every 2–3 minutes.

# Cont...

**RETRACTION:** Retraction is a phenomenon of the uterus in labor in which the muscle fibers are permanently shortened. Unlike any other muscles of the body, the uterine muscles have this property to become shortened once and for all.

Contraction is a temporary reduction in length of the fibers, which attain their full length during relaxation. In contrast, retraction results in permanent shortening and the fibers are shortened once and for all.

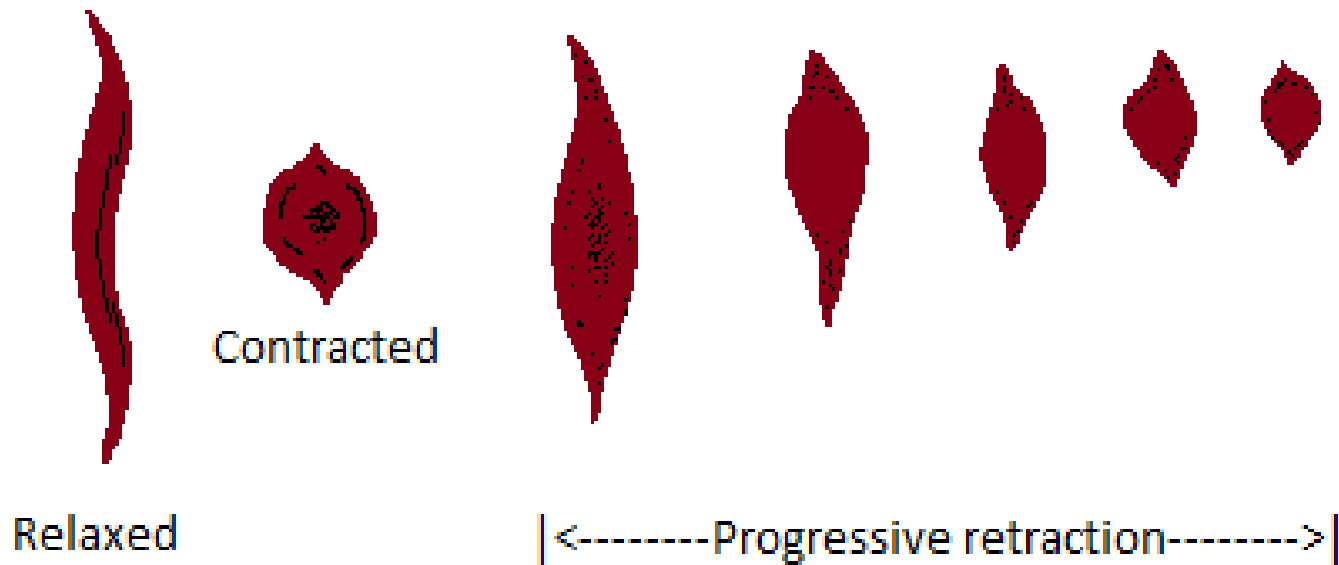
# Cont....

The net effects of retraction in normal labor are:

- Essential property in the formation of lower uterine segment and dilatation and effacement of the cervix.
- To maintain the descent of the presenting part made by the uterine contractions and to help in ultimate expulsion of the fetus.
- To reduce the surface area of the uterus favoring separation of placenta.
- Effective hemostasis after the separation of the placenta.

# RETRACTION PROCESS

[pregnancyandlabour.blogspot.com](http://pregnancyandlabour.blogspot.com)



Showing phenomenon of contraction and retraction of uterine muscle fibres during labour

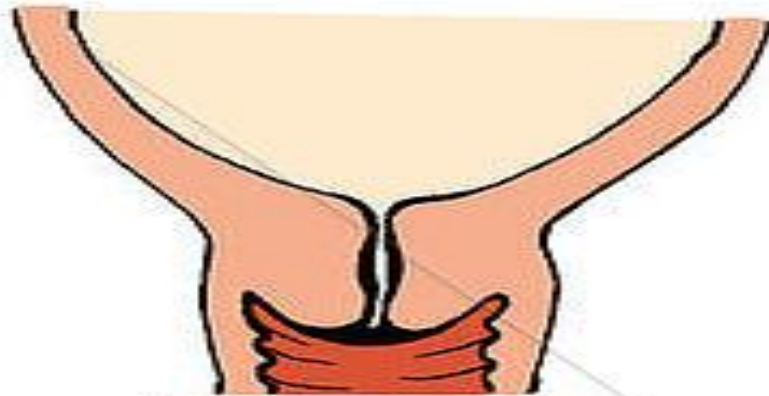

# EVENTS IN FIRST STAGE OF LABOR

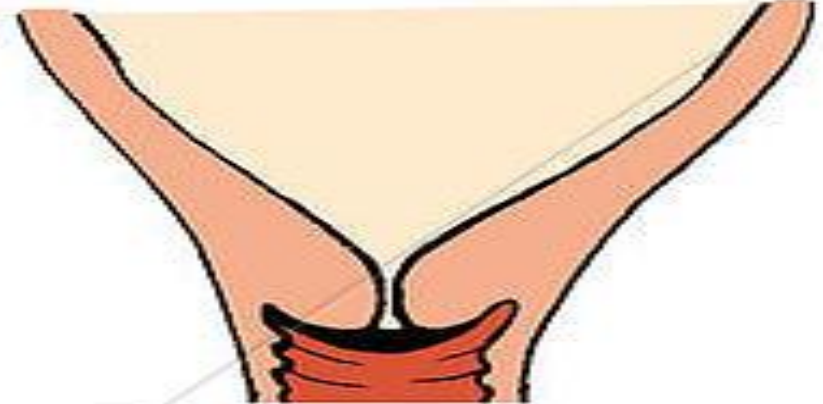The first stage is chiefly concerned with the preparation of the birth canal so as to facilitate expulsion of the fetus in the second stage. The main events that occur in the first stage are—

- (a) dilatation and effacement of the cervix  
and
- (b) full formation of lower uterine segment.

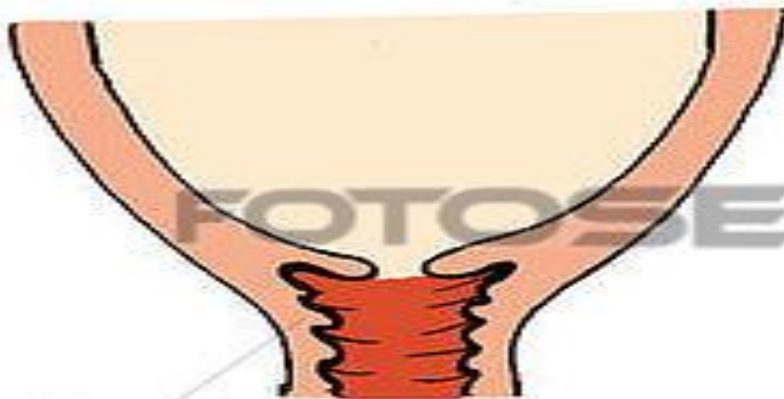# Cont...



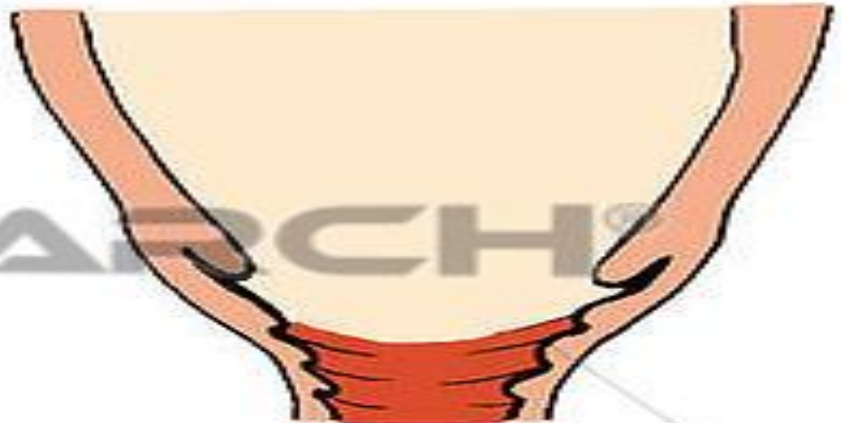Before labor  
0% effacement



Early effacement  
30%



Complete effacement  
100%



Complete  
dilation

cog12024 www.fotosearch.com

---

## Formation of upper and lower uterine segments

- The upper uterine segment, having been formed from the body of the fundus, is mainly concerned with contraction and retraction; it is thick and muscular.
- The lower uterine segment is formed of the isthmus and the cervix, and is about 8-10 cm in length. The lower segment is prepared for distention and dilatation.
- The muscle content reduces from the fundus to the cervix, where it is thinner.

# Cont...

1. DILATATION OF THE CERVIX: Prior to the onset of labor, in the prelabor phase (Phase-1) there may be a certain amount of dilatation of cervix, especially in multiparae and in some primigravidae. Actual Factors Responsible are:

- ☐ Uterine contraction and retraction
- ☐ Fetal axis pressure
- ☐ Bag of membranes



# Uterine contraction and retraction

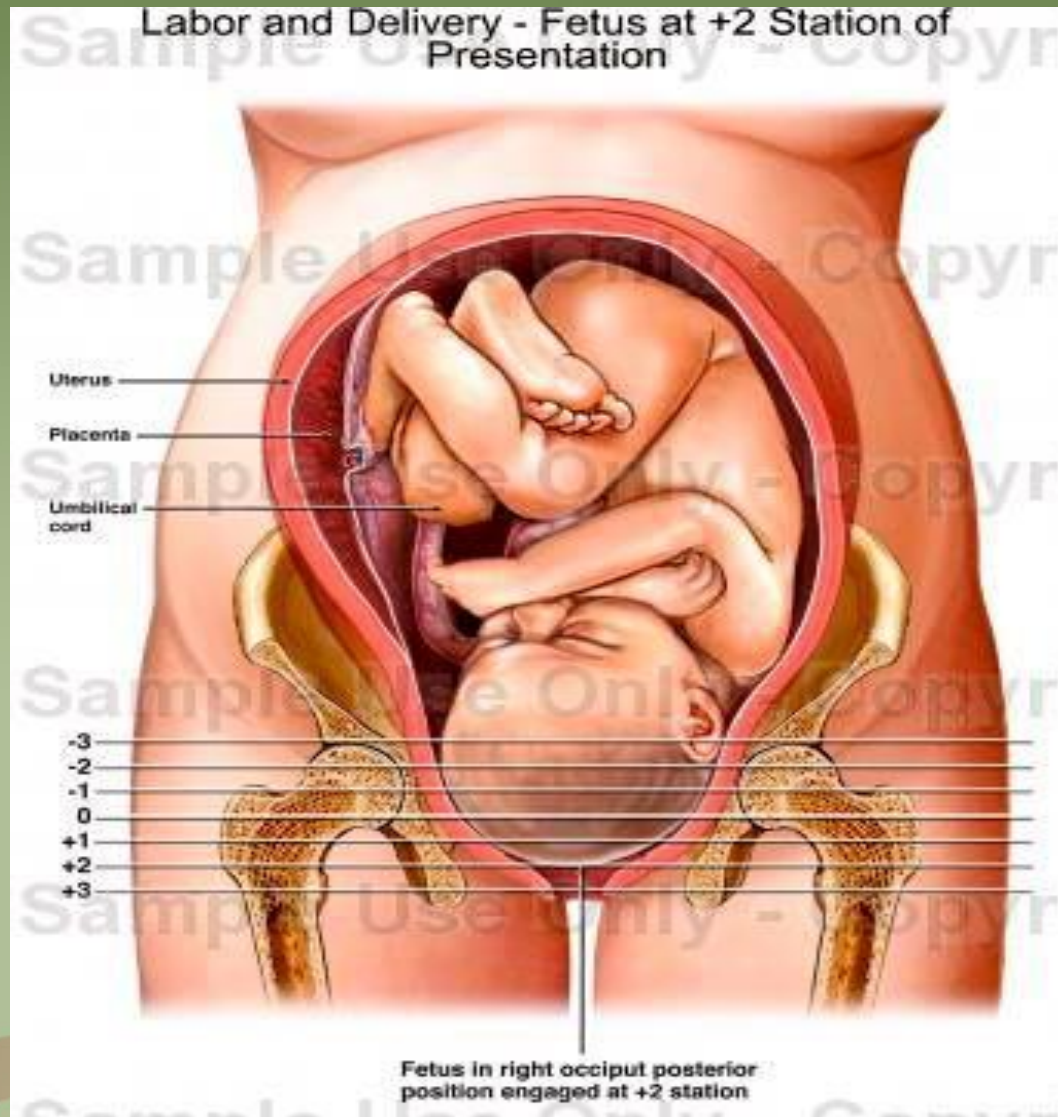
The longitudinal muscle fibers of the upper segment are attached with circular muscle fibers of the lower segment and upper part of the cervix in a bucket-holding fashion. Thus, with each uterine contraction, not only the canal is opened up from above down but also it becomes shortened and retracted. There is some co-ordination between fundal contraction and cervical dilatation called “polarity of uterus” . While the upper segment contracts, retracts and pushes the fetus, the lower segment and the cervix dilate in response to the forces of contraction of upper segment.

# Fetal axis pressure

In labor with longitudinal lie and with well-fitted (flexed) fetal head on the cervix, fetal vertebral column is straightened by the contractions of the circular muscle fibers of the body of the uterus. This allows the fundal strong contraction force to be transmitted through the fetal podalic pole and vertebral column to the well-fitted fetal head. This causes mechanical stretching of the lower segment and opening up (dilatation) of the cervical canal.



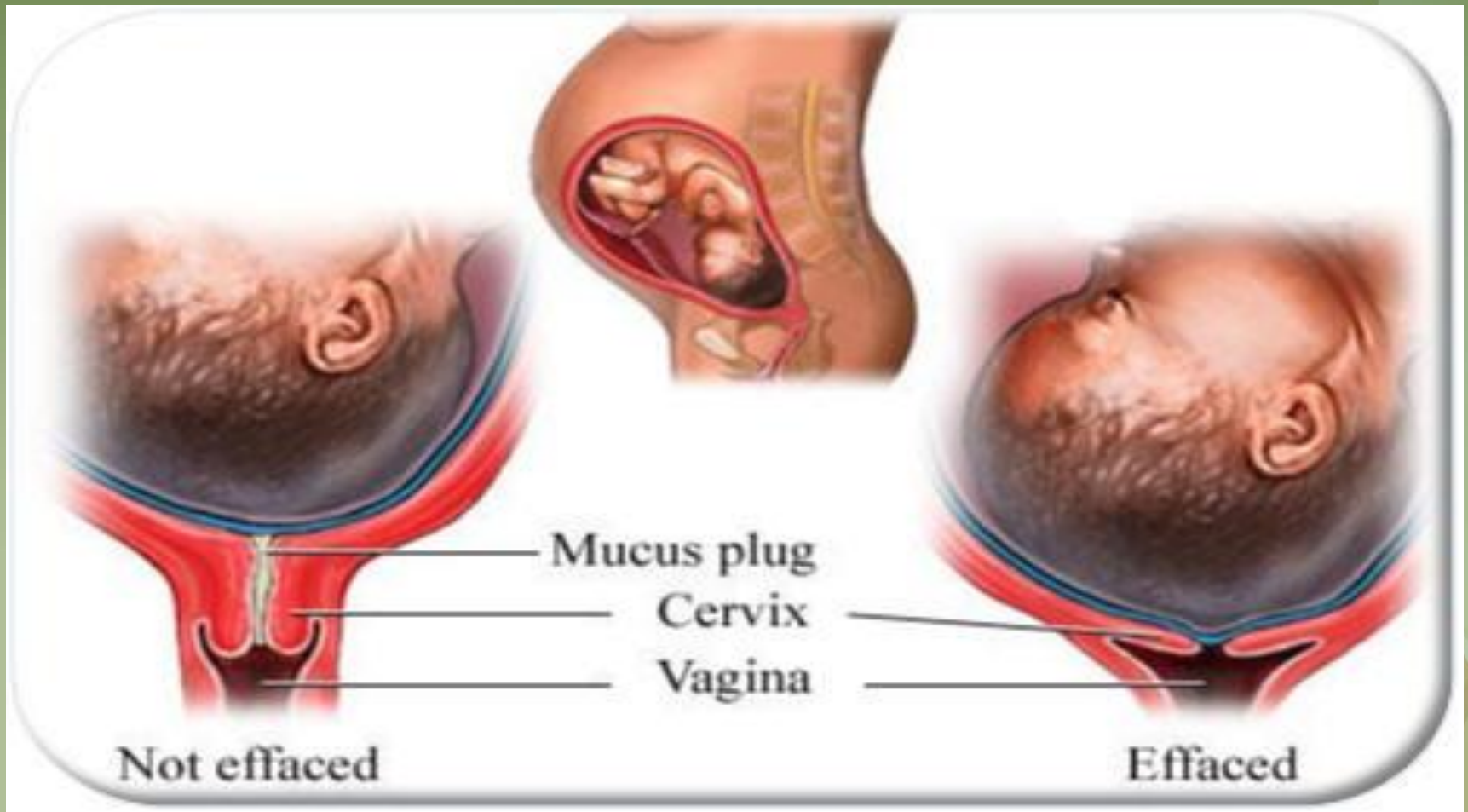
# FETAL AXIS PRESSURE



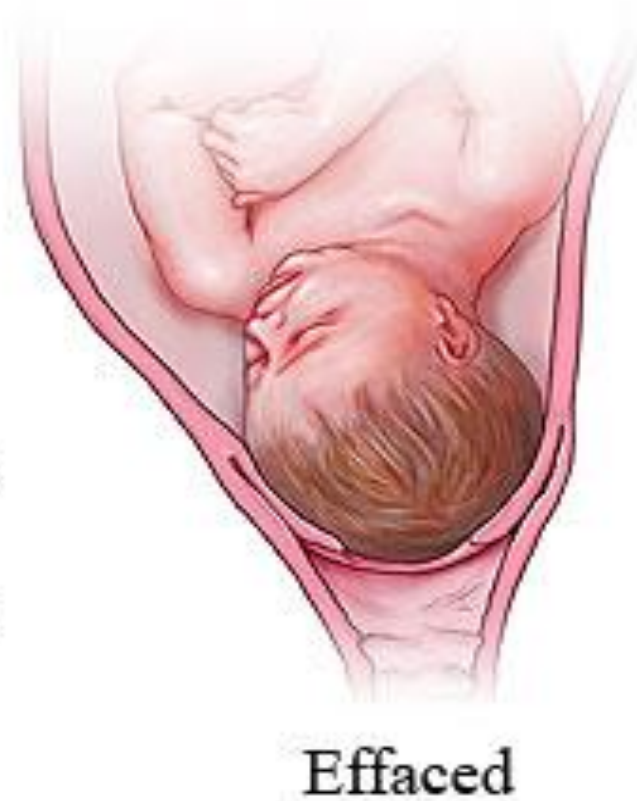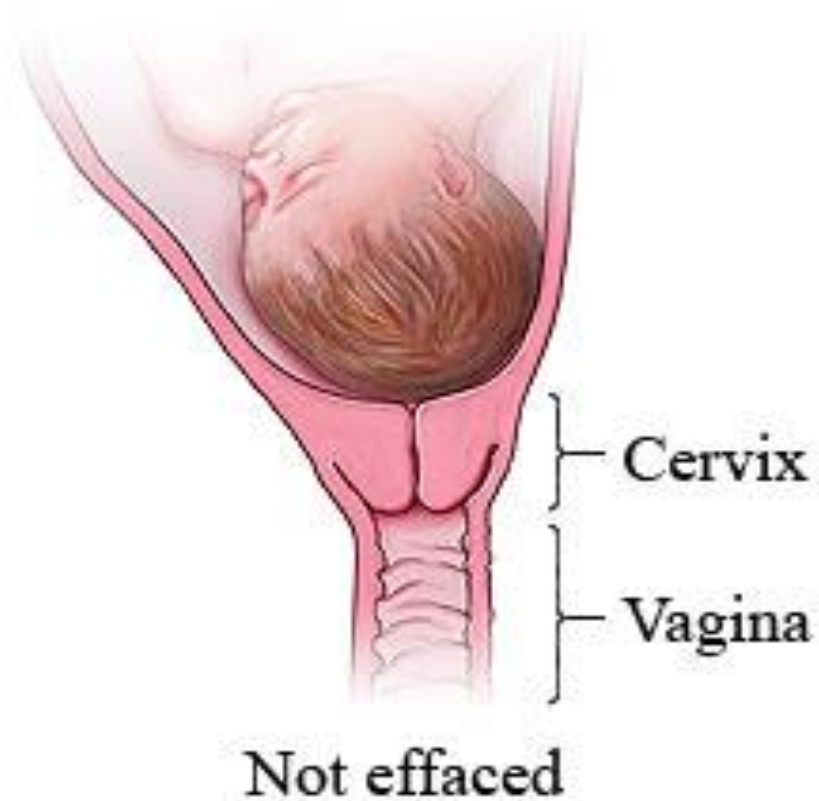# Cont...

**EFFACEMENT OR TAKING UP OF CERVIX:**  
Effacement is the process by which the muscular fibers of the cervix are pulled upward and merges with the fibers of the lower uterine segment. The cervix becomes thin during first stage of labor or even before that in primigravidae. In primigravidae, effacement precedes dilatation of the cervix, whereas in multiparae, both occur simultaneously. Expulsion of mucus plug is caused by effacement.

# CERVICAL EFFACEMENT



# Cont...





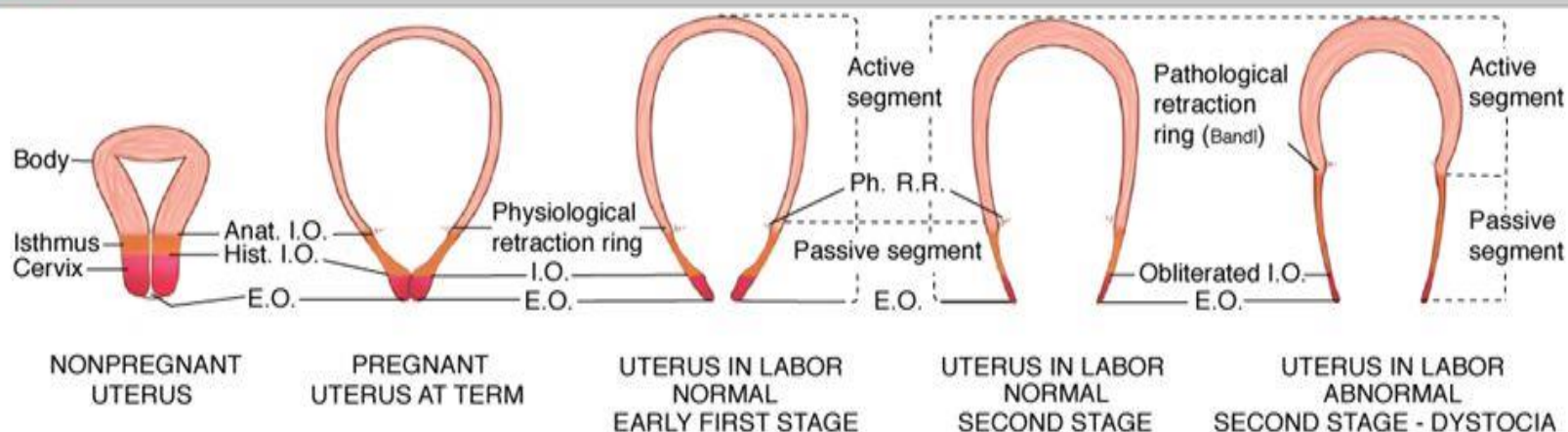
# Cont...

2. LOWER UTERINE SEGMENT: Before the onset of labor, there is no complete anatomical or functional division of the uterus. During labor the demarcation of an active upper segment and a relatively passive lower segment is more pronounced. The wall of the upper segment becomes progressively thickened with progressive thinning of the lower segment. This is pronounced in late first stage, especially after rupture of the membranes and attains its maximum in second stage. A distinct ridge is produced at the junction of the two, called physiological retraction ring which should not be confused with the pathological retraction ring—a feature of obstructed labor.

# Formation of the Lower Uterine Segments

- derived from the isthmus which is about 1 cm in nonpregnant uterus, and when the labor is started, with regular contractions of the upper uterine segment, it distended to 7 to 10cm.

Figure 6-5





# EVENTS IN SECOND STAGE OF LABOR

The second stage begins with the complete dilatation of the cervix and ends with the expulsion of the fetus. This stage is concerned with the descent and delivery of the fetus through the birth canal.

Second stage has two phases:

(1) Propulsive—from full dilatation until head touches the pelvic floor.

(2) Expulsive—since the time mother has irresistible desire to “bear down” and push until the baby is delivered.

# Cont...

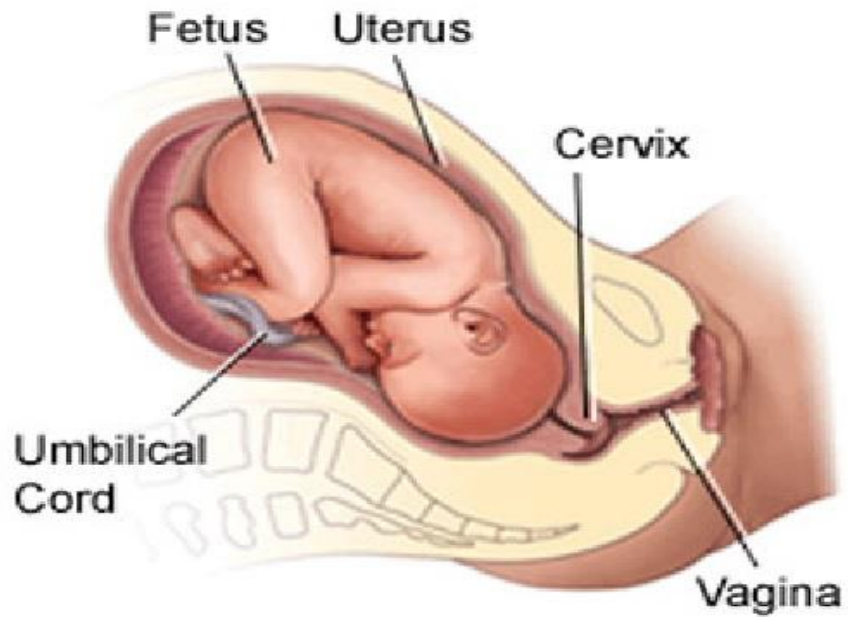
With the full dilatation of the cervix, the membranes usually rupture and there is escape of good amount of liquor amnii. The volume of the uterine cavity is thereby reduced. Simultaneously, uterine contraction and retraction become stronger. Delivery of the fetus is accomplished by the downward thrust offered by uterine contractions supplemented by voluntary contraction of abdominal muscles against the resistance offered by bony and soft tissues of the birth canal. There is always a tendency to push the fetus back into the uterine cavity by the elastic recoil of the tissue of the vagina and the pelvic floor.

# Cont...

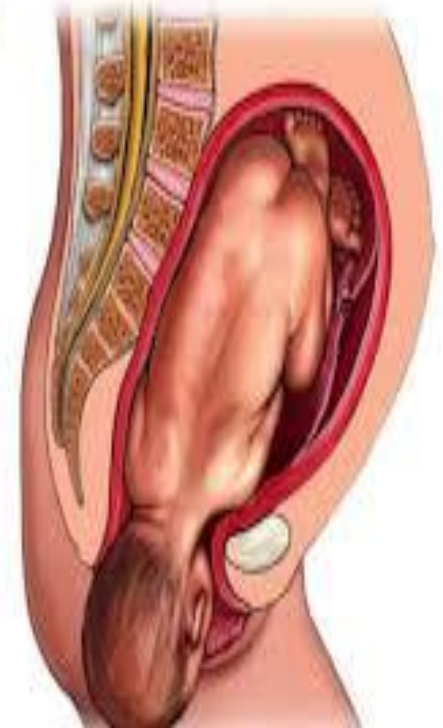
This is effectively counterbalanced by the power of retraction. Thus, with increasing contraction and retraction, the upper segment becomes more and more thicker with corresponding thinning of lower segment. Endowed with power of retraction, the fetus is gradually expelled from the uterus against the resistance offered by the pelvic floor. After the expulsion of the fetus, the uterine cavity is permanently reduced in size only to accommodate the afterbirths. The expulsive force of uterine contractions is added by voluntary contraction of the abdominal muscles called “bearing down” efforts.

# Cont...

## Initial (Latent) Phase



## crowning



# EVENTS IN THIRD STAGE OF LABOR

The third stage of labor comprises the phase of placental separation; its descent to the lower segment and finally its expulsion with the membranes.

**PLACENTAL SEPARATION:** At the beginning of labor, the placental attachment roughly corresponds to an area of 20 cm (8") in diameter. There is no appreciable diminution of the surface area of the placental attachment during first stage. During the second stage, there is slight but progressive diminution of the area following successive retractions, which attains its peak immediately following the birth of the baby. The cavity is much reduced to accommodate only the afterbirths.

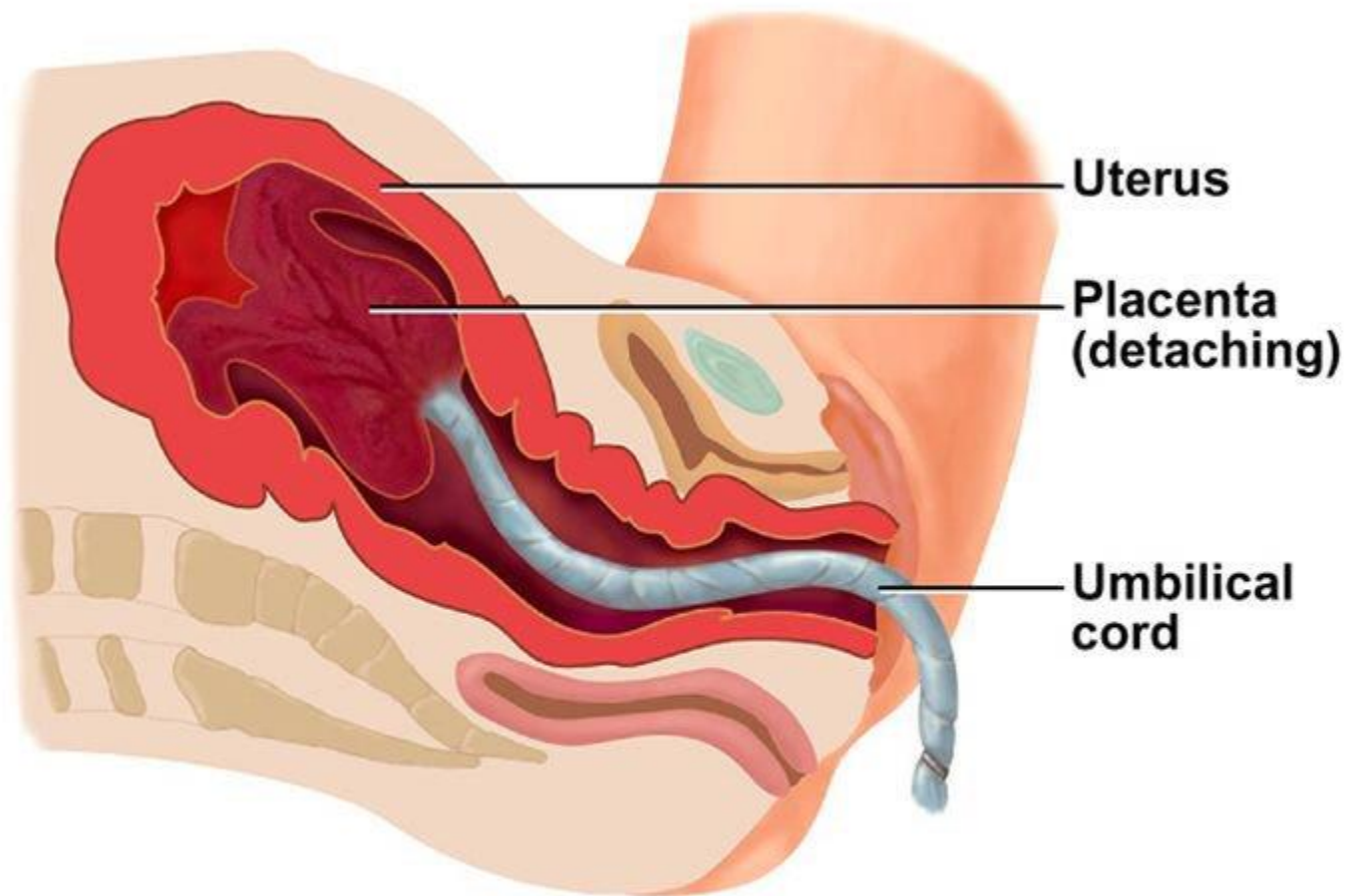


# Cont...

Mechanism of separation: Marked retraction reduces effectively the surface area at the placental site to about its half. But as the placenta is inelastic, it cannot keep pace with such an extent of diminution resulting in its buckling. A shearing force is instituted between the placenta and the placental site which brings about its ultimate separation. The plane of separation runs through deep spongy layer of decidua basalis so that a variable thickness of decidua covers the maternal surface of the separated placenta. There are two ways of separation of placenta:



# Stages of Labor -- Placental Stage



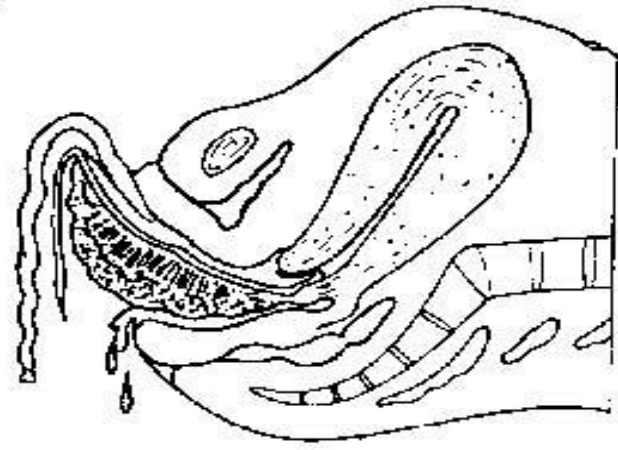
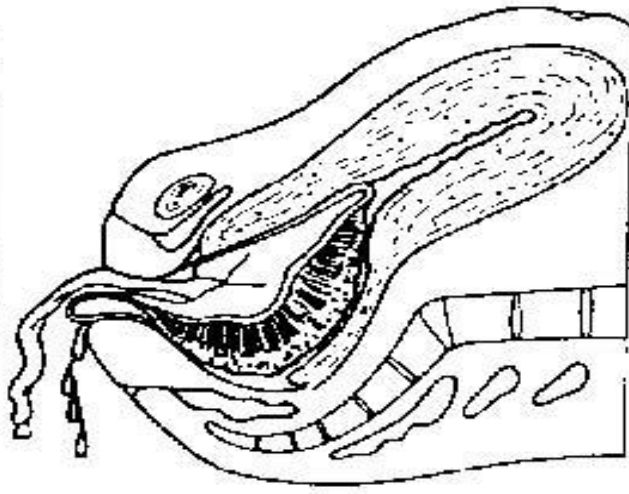
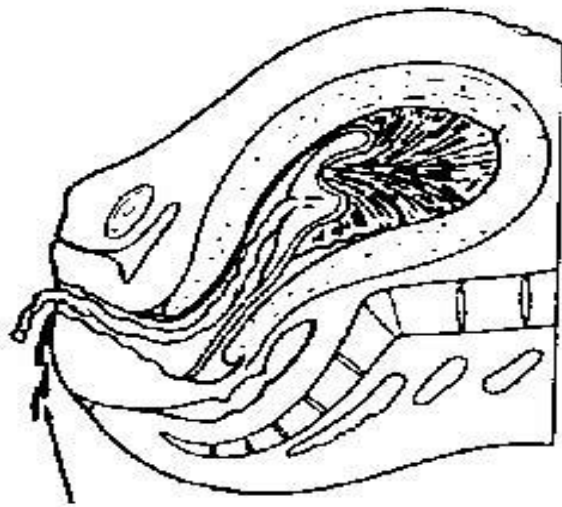
- Uterine contractions continue causing placental separation
  - 350 mL blood loss is normal, but postpartum hemorrhaging occurs if expulsion is not completed

# Cont...

(1) Central separation (Schultze): Detachment of placenta from its uterine attachment starts at the center resulting in opening up of few uterine sinuses and accumulation of blood behind the placenta (retroplacental hematoma). With increasing contraction, more and more detachment occurs facilitated by weight of the placenta and retroplacental blood until whole of the placenta gets detached.

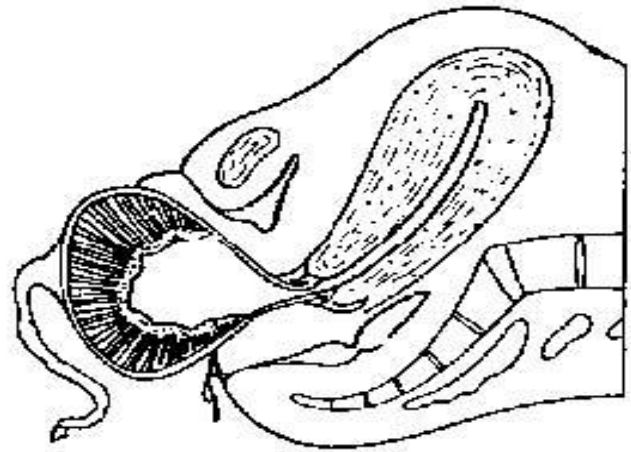
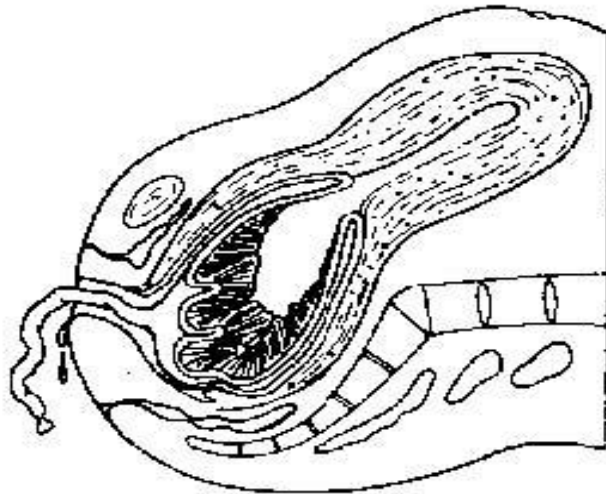
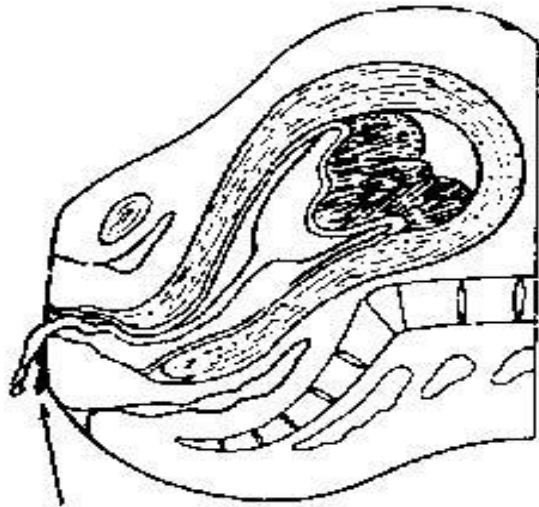
(2) Marginal separation (Mathews-Duncan): Separation starts at the margin as it is mostly unsupported. With progressive uterine contraction, more and more areas of the placenta get separated. Marginal separation is found more frequently.

# Duncan mechanism



Bleeding

# Schultze mechanism



Bleeding

# Cont...

## SEPARATION OF THE MEMBRANES:

The membranes, which are attached loosely in the active part, are thrown into multiple folds. Those attached to the lower segment are already separated during its stretching. The separation is facilitated partly by uterine contraction and mostly by weight of the placenta as it descends down from the active part. The membranes so separated carry with them remnants of decidua vera giving the outer surface of the chorion its characteristic roughness.

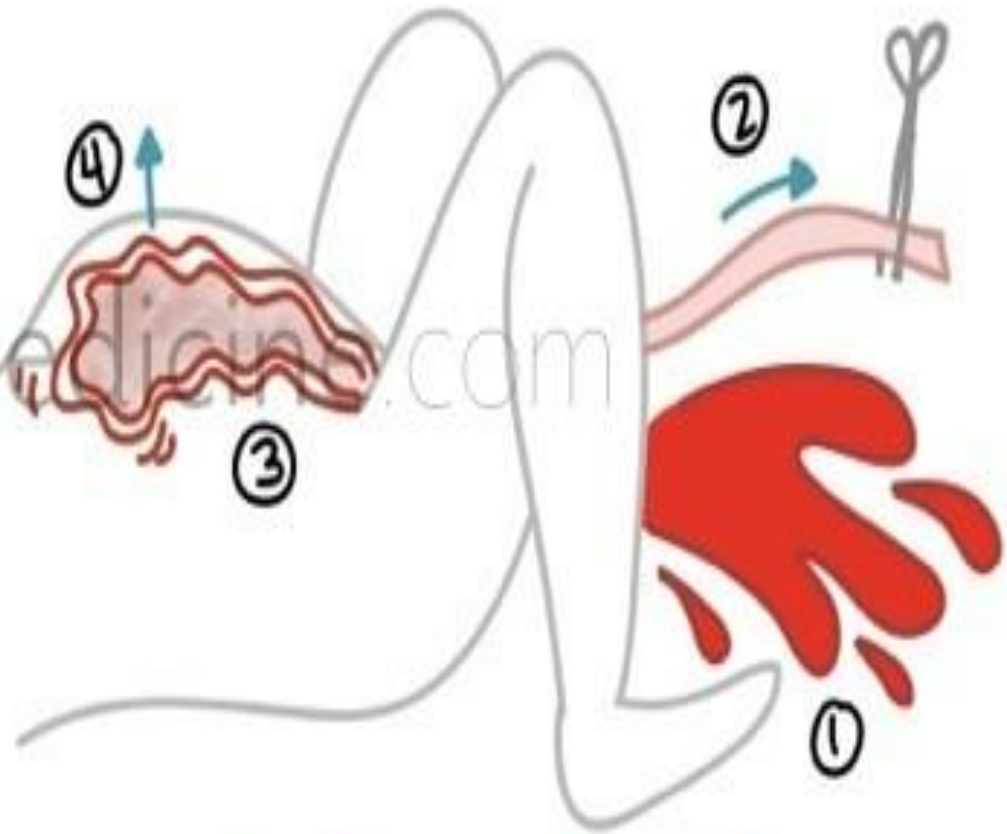
# Cont...

**EXPULSION OF PLACENTA:** After complete separation of the placenta, it is forced down into the flabby(loose) lower uterine segment or upper part of the vagina by effective contraction and retraction of the uterus. Thereafter, it is expelled out either by voluntary contraction of abdominal muscles (bearing down efforts) or by manual procedure.



# Signs of the 3<sup>rd</sup> stage of labour

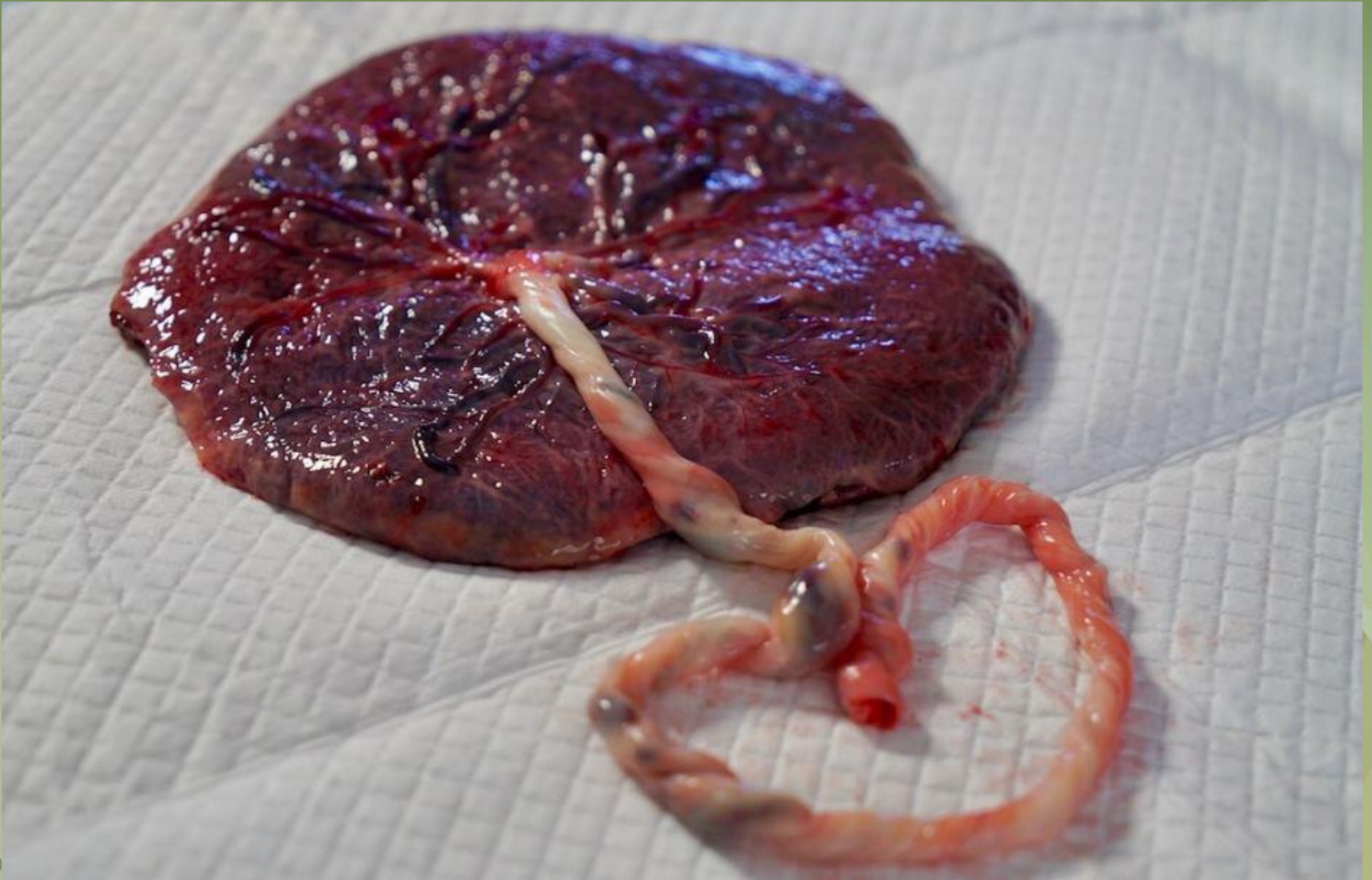- ① Gush of blood
- ② Cord lengthening
- ③ Globular + firm uterus
- ④ Uterus rises anteriorly



⚠ Should happen within 30min of delivery of infant



# PLACENTA



# Cont...

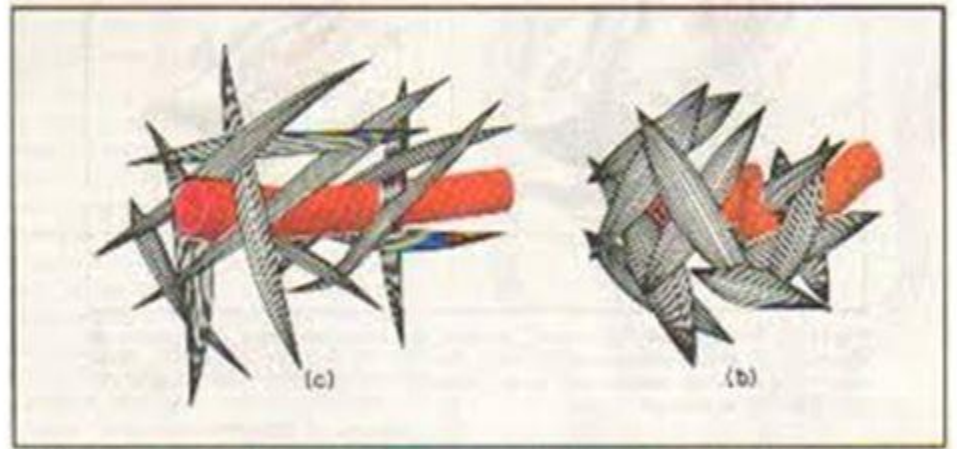
Mechanism of control of bleeding: After placental separation, innumerable torn sinuses which have free circulation of blood from uterine and ovarian vessels have to be obliterated. The occlusion is affected by complete retraction whereby the arterioles, as they pass tortuously through the interlacing intermediate layer of the myometrium, are literally clamped. It (living ligature) is the principal mechanism of hemostasis. However, thrombosis occurs to occlude the torn sinuses, a phenomenon, which is facilitated by hypercoagulable state of pregnancy.

# Mechanisms to control bleeding

1. Effective retraction of uterine muscles :  
Living ligatures

2. Thrombosis of torn sinuses

3. Myotamponade:  
apposition of walls of the uterus



# MANAGEMENT OF NORMAL LABOR

General considerations: Labor events have got great psychological, emotional and social impact to the woman and her family. She experiences stress, physical pain and fear of dangers. The caregiver should be tactful, sensitive and respectful to her. Continuous emotional support during labor may reduce the need for analgesia and decrease the rate of operative delivery. Privacy must be maintained. She is explained about the events from time to time. Comfortable environment, skill and confidence of the caregiver and appropriate support are all essential so that a woman can give birth with dignity.



# Cont...

Management of normal labor aims at maximal observation with minimal active intervention. The idea is to maintain the normalcy and to detect any deviation from the normal at the earliest possible moment.

**ANTISEPTICS AND ASEPSIS:** surgical cleanliness and asepsis on the part of the patients and the attendants involved in the delivery process are to be maintained.

**Patient care:** Shaving or hair clipping of the vulva is done. The vulva and the perineum are washed liberally with soap and water and then with 10% Dettol solution or Hibitane (chlorhexidine).



# Cont....

The woman should take a shower or bath, wear laundered gown and stay mobile. Throughout labor she is given continued encouragement and emotional support. Antiseptic and aseptic precautions are to be taken during vaginal examination and during conduction of delivery.

**VAGINAL EXAMINATION IN LABOR:** First vaginal examination should be done by a senior doctor to be more reliable and informative. The examination is done with the patient lying in dorsal position.

# Cont....

- PRELIMINARIES:
- (1) Toileting—Hands and forearms should be washed with soap and running water. The procedure should take at least 3 minutes.
- (2) Sterile pair of gloves is donned.
- (3) Vulval toileting is performed. Vulva should once more be swabbed from before backward with antiseptic lotion like 10% Dettol.
- (4) Gloved middle and index fingers of the right hand smeared liberally with antiseptic cream like Cetavlon are introduced into the vagina after separating the labia by two fingers of the left hand.

# Cont...

(5) Complete examination should be done before fingers are withdrawn. (6) Vaginal examination should be kept as minimum as possible to avoid risks of infection.

The following informations are to be noted and recorded carefully (Partograph):

- ☐ Degree of cervical dilatation in centimeters. It is marked with a cross (×) on the partograph at 4 cm dilatation.
- ☐ Degree of effacement of cervix.

# Cont...

- Status of membranes and if ruptured—color of the liquor. Color of the liquor in the partograph is recorded as—I: membranes intact; R: membranes ruptured; C: liquor clear; M: liquor meconium stained; B: liquor blood stained.
- Presenting part and its position by noting the fontanels and sagittal suture in relation to the quadrants of the pelvis.
- Lambda or Posterior fontanel is recognized by the big “Y” shaped three suture lines. Bregma or anterior fontanel is recognized by diamond-shaped area and the presence of four suture lines.

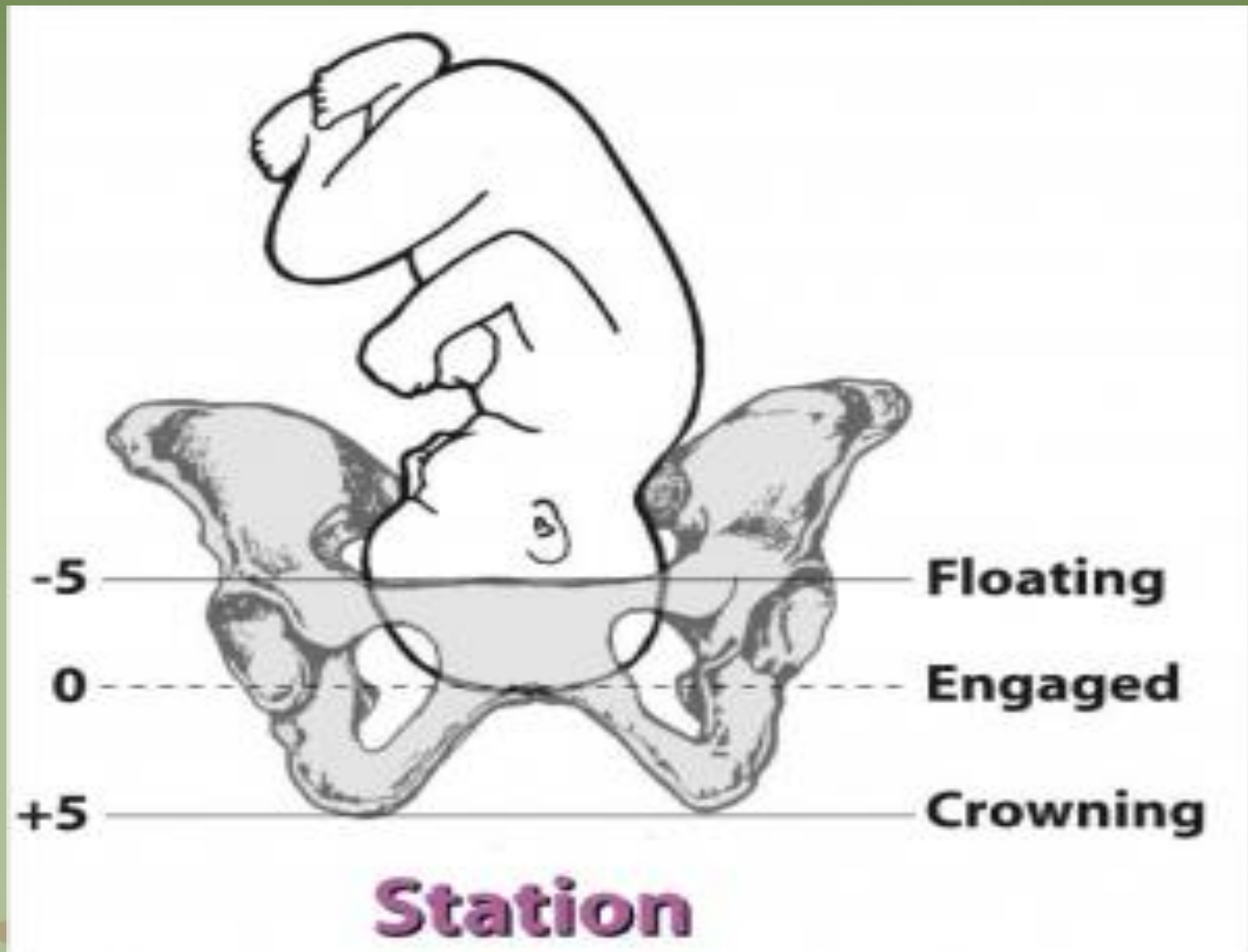
# Cont...

- Caput or molding of the head.
- Station of the head in relation to ischial spines.

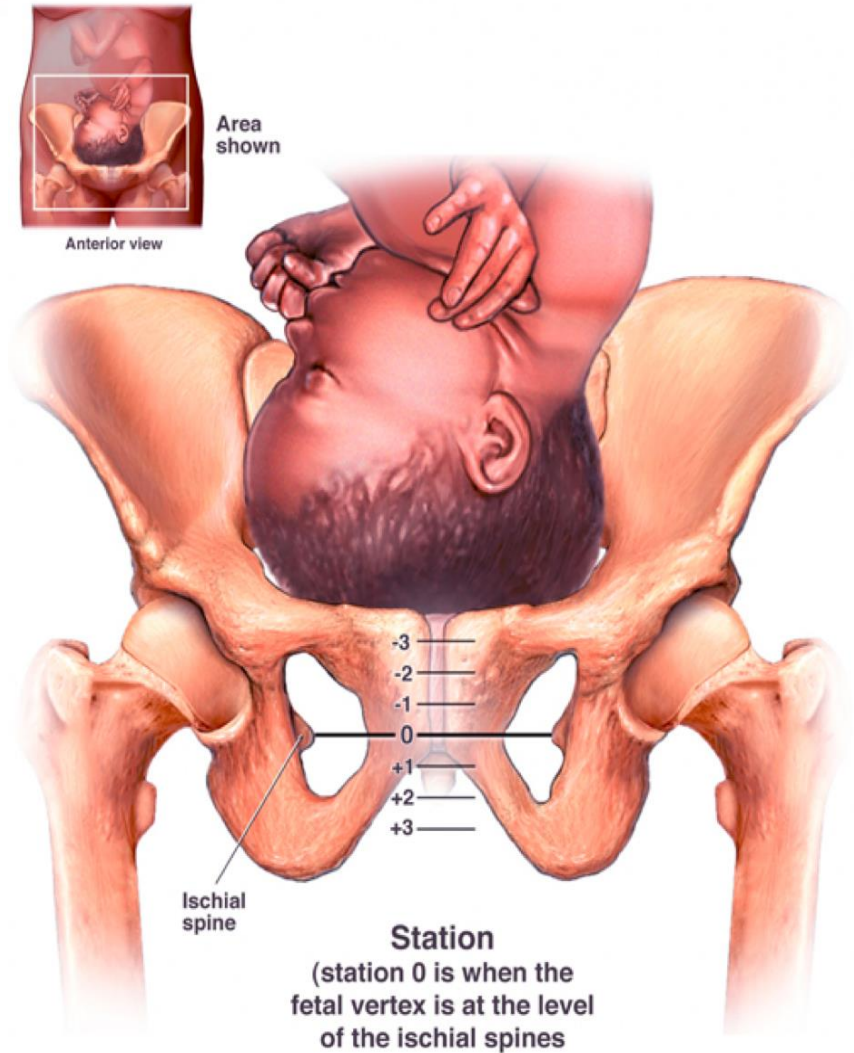
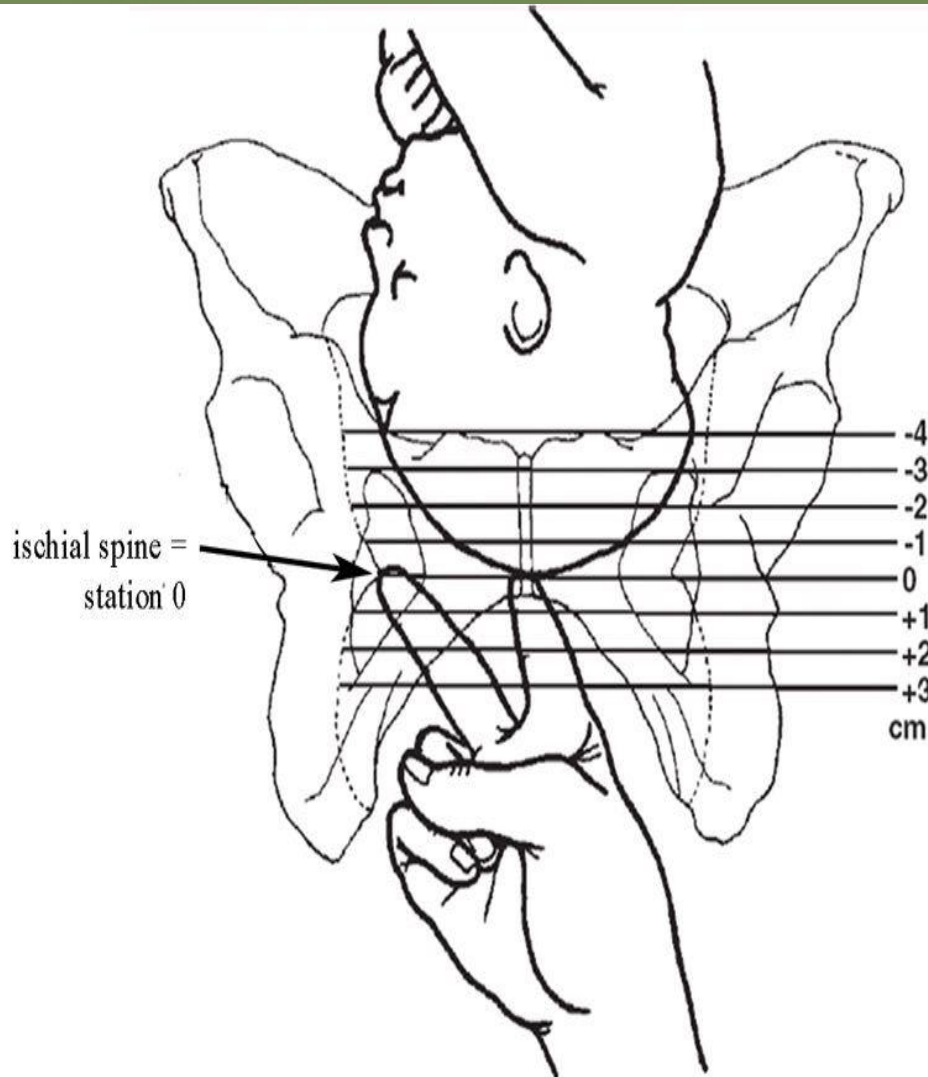
Spines are the most prominent bony projections felt on internal examination. The level of ischial spines is the halfway between the pelvic inlet and outlet. This level is known as station zero (0). The levels above and below the spines are divided into fifths to represent centimeters. The station is said to be “O” if the presenting part is at the level of the spines. The station is stated in minus figures, if it is above the spines (–1 cm, –2 cm, –3 cm, –4 cm and –5 cm) and in plus figures if it is below the spines (+1 cm, +2 cm, +3 cm, +4 cm and +5 cm).



# STATIONS OF HEAD



# Cont...



# INDICATIONS OF VAGINAL EXAMINATION

Whatever aseptic technique is employed, there is always some chance of introducing infection especially after rupture of the membranes. Hence vaginal examination should be restricted to a minimum.

- At the onset of labor
- The progress of labor
- Following rupture of the membranes

# MANAGEMENT OF THE FIRST STAGE

**PRINCIPLES:** (1) Noninterference with watchful expectancy so as to prepare the patient for natural birth. (2) To monitor carefully the progress of labor, maternal conditions and fetal behavior so as to detect any intrapartum complication early.

**PRELIMINARIES:** This consists of basic evaluation of the current clinical condition. Enquiry is to be made about the onset of labor pains or leakage of liquor, if any. Thorough general and obstetrical examinations including vaginal examination are to be carried out and recorded. Records of antenatal visits, investigation reports and any specific treatment given, if available, are to be reviewed.

# ACTUAL MANAGEMENT

- ☐ General—(a) Antiseptic dressing (b) Encouragement, emotional support and assurance are given to keep up the morale. (c) Constant supervision is ensured.
- ☐ Bowel
- ☐ Rest and ambulation
- ☐ Diet
- ☐ Bladder care
- ☐ Relief of pain- common analgesic drug used is pethidine 50–100 mg intramuscularly when the pain is well established in the active phase of labor. If necessary, it is repeated after 4 hours. Pethidine is an effective analgesic as well as a sedative.



# Cont....

Metoclopramide 10 mg IM is commonly given to combat vomiting due to pethidine. Pethidine crosses the placenta and is a respiratory depressant to the neonate. The drug should not be given if delivery is anticipated within 2 hours.

□ Assessment of progress of labor and partograph recording.

Abdominal palpation—

(a) Uterine contractions as regard the frequency, intensity and duration are assessed.

(b) Pelvic grip

(c) Shifting of the maximal intensity of the fetal heart beat downward and medially.

# Cont...

To note the fetal well-being: □ Fetal heart rate (FHR) along with its rhythm and intensity should be noted every half hour in the first stage and every 15 minutes in second stage or following rupture of the membranes.

Normal fetal heart rate ranges from 110 to 150 per minute.

**TO WATCH THE MATERNAL CONDITION:** Routine checkup includes: (a) to record 2 hourly pulse, blood pressure and temperature; (b) to observe the tongue periodically for hydration (c) to note the urine output, and (d) IV fluids, drugs.

# MANAGEMENT OF THE SECOND STAGE

The transition from the first stage to the second stage is evidenced by the following features:

- ☐ Increasing intensity of uterine contractions
- ☐ Bearing-down efforts
- ☐ Urge to push or defecate with descent of the presenting part
- ☐ Complete dilatation of the cervix as evidenced on vaginal examination.

PRINCIPLES: (1) To assist in the natural expulsion of the fetus slowly and steadily,  
(2) To prevent perineal injuries.

# Cont...

## GENERAL MEASURES:

- The patient should be in bed.
- Constant supervision is mandatory and the FHR is recorded at every 5 minutes.
- Vaginal examination is done at the beginning of the second stage not only to confirm its onset but to detect any accidental cord prolapse. The position and the station of the head are once more to be reviewed and the progressive descent of the head is ensured.

# Cont...

## PREPARATION FOR DELIVERY

— Position: Positions of the woman during delivery may be lateral, squatting or partial sitting ( $45^\circ$ ). Dorsal position with  $15^\circ$  left lateral tilt is commonly favored as it avoids aortocaval compression and facilitates pushing effort.

— The nurse scrubs up and puts on sterile gown, mask and gloves and stands on the right side of the table.

— Toileting the external genitalia and inner side of the thighs is done with cotton swabs soaked in Savlon or Dettol solution.



# Cont...

One sterile sheet is placed beneath the buttocks of the patient and one over the abdomen. Essential aseptic procedures are remembered as three Cs: (a) Clean hands, (b) Clean surface and (c) Clean cutting and ligaturing of the cord.

— To catheterize the bladder, if it is full.

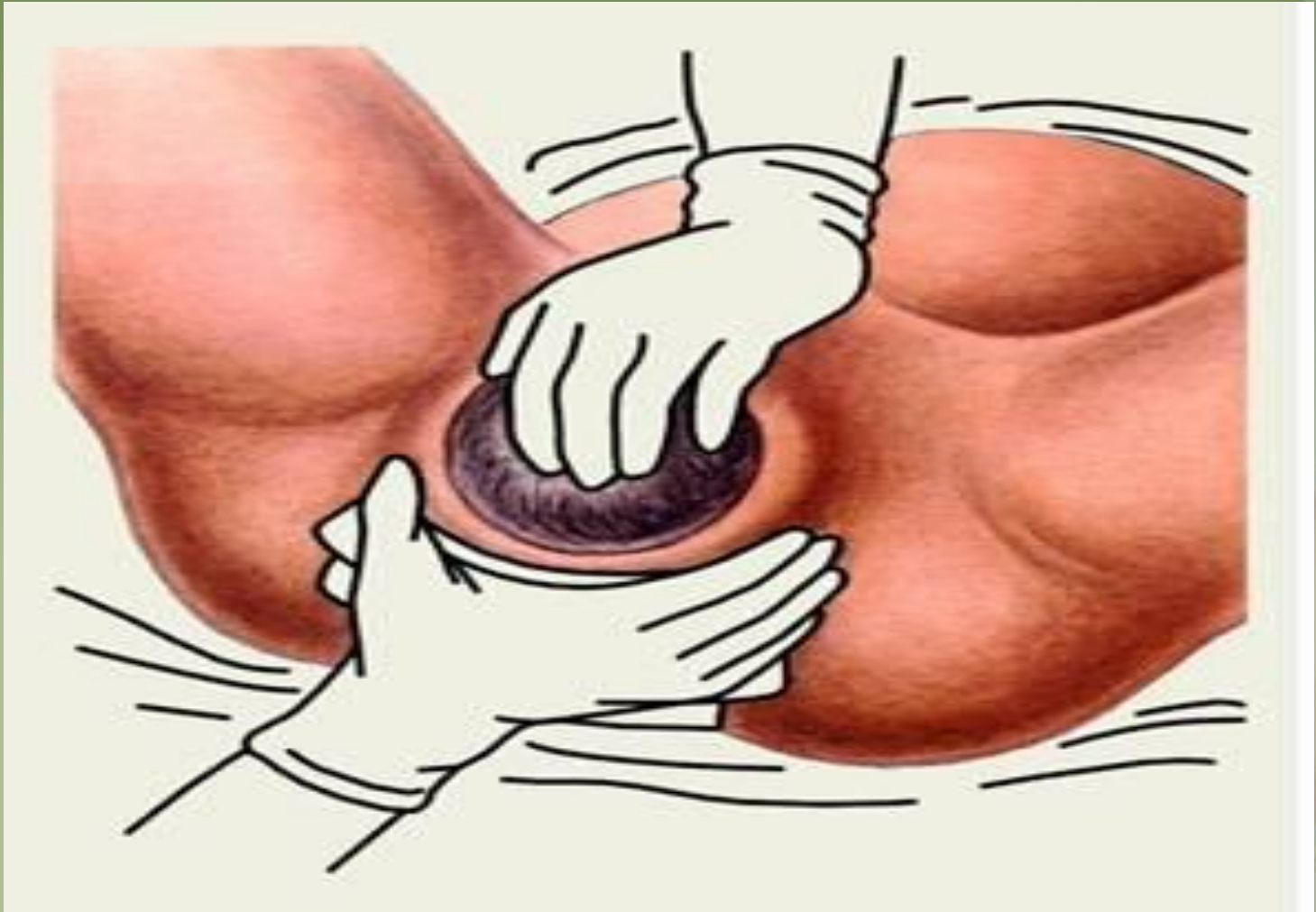**CONDUCTION OF DELIVERY:** The assistance required in spontaneous delivery is divided into three phases :

- ☐ Delivery of the head
- ☐ Delivery of the shoulders
- ☐ Delivery of the trunk

# Cont...

- Delivery of the head: The principles to be followed are to maintain flexion of the head, to prevent its early extension and to regulate its slow escape out of the vulval outlet.
- The patient is encouraged for the bearing-down efforts during uterine contractions. This facilitates descent of the head.
- When the scalp is visible for about 5 cm in diameter, flexion of the head is maintained during contractions. This is achieved by pushing the occiput downward and backward by using thumb and index fingers of the left hand while pressing the perineum by the right palm with a sterile vulval pad. If the patient passes stool, it should be cleaned and the region is washed with antiseptic lotion.

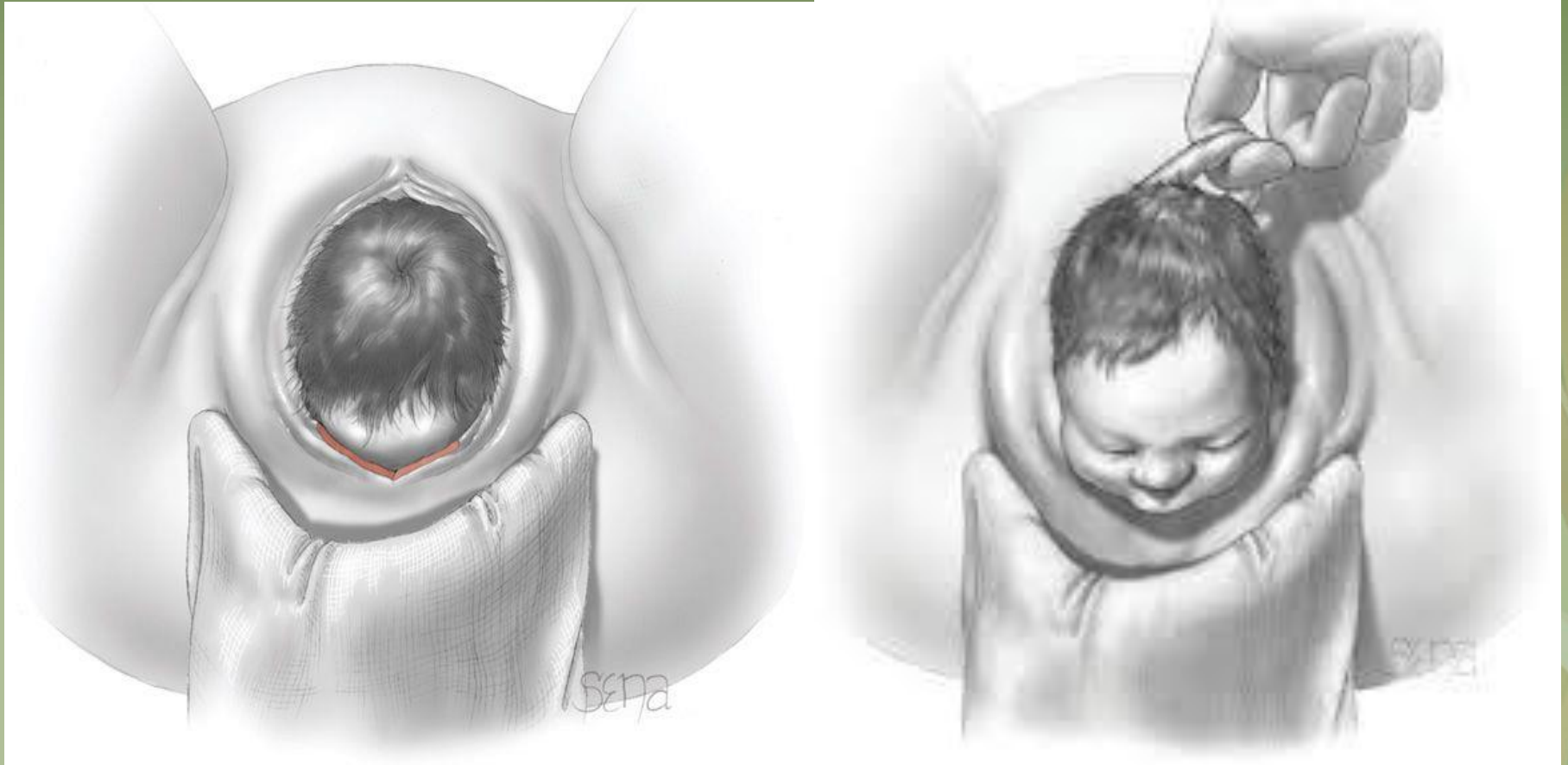
# RITGEN'S MANEUVER



# Cont...

□ The process is repeated during subsequent contractions until the subocciput is placed under the symphysis pubis. At this stage, the maximum diameter of the head (biparietal diameter) stretches the vulval outlet without any recession of the head even after the contraction is over, and it is called “crowning of the head”. The purpose of increasing the flexion of the head is to ensure that the small suboccipitofrontal diameter 10 cm (4") distends the vulval outlet instead of larger occipitofrontal diameter 11.5 cm.

# DELIVERY OF HEAD

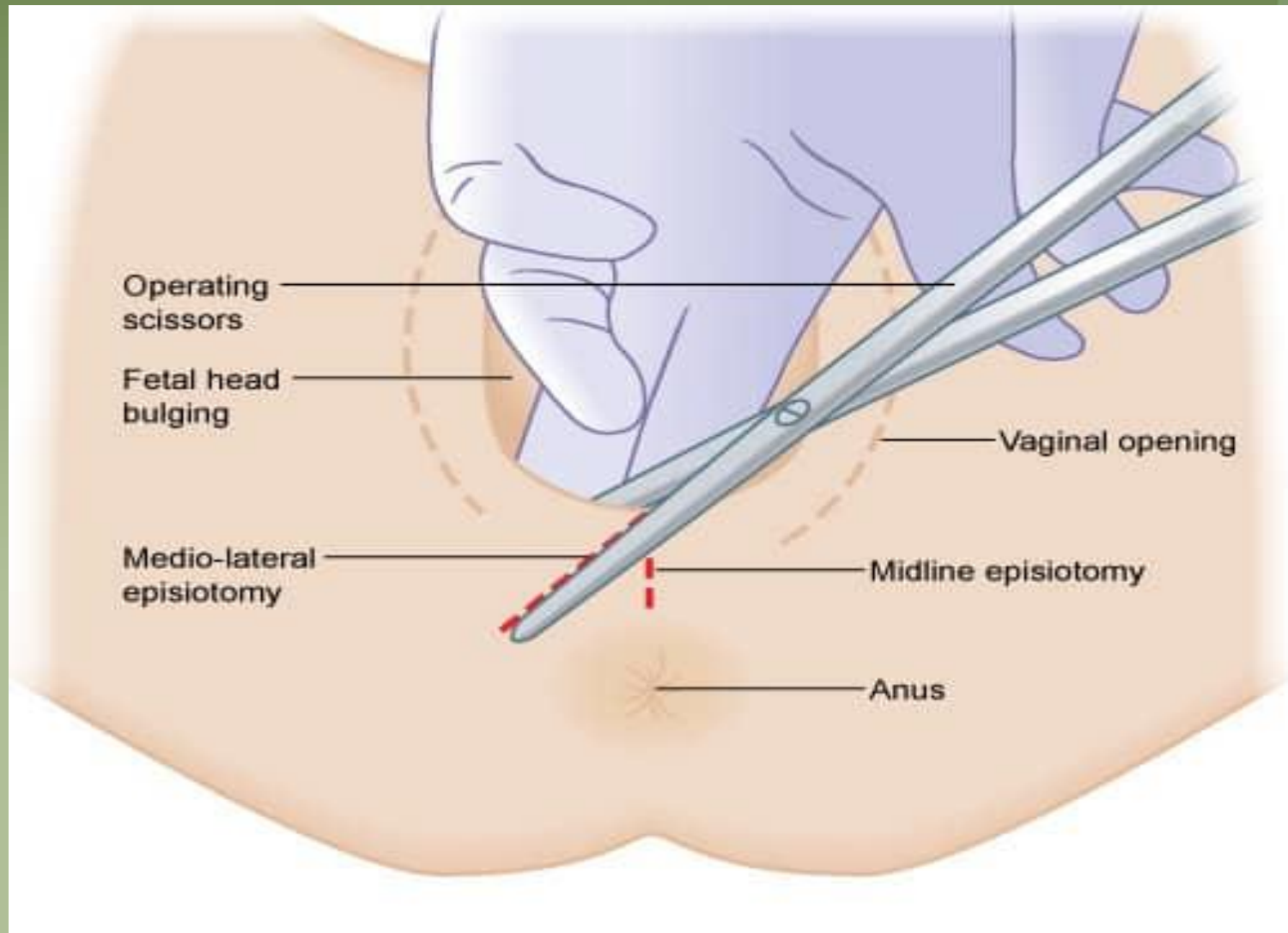




# Cont...

- When the perineum is fully stretched and threatens to tear especially in primigravidae, episiotomy is done at this stage after prior infiltration with 10 mL of 1% lignocaine. Bulging thinned out perineum is a better criterion than the visibility of 4–5 cm of scalp to decide the time of performing episiotomy.
- Slow delivery of the head in between the contractions is to be regulated. The forehead, nose, mouth and the chin are thus born successively over the stretched perineum by extension.

# EPISIOTOMY



# Cont....

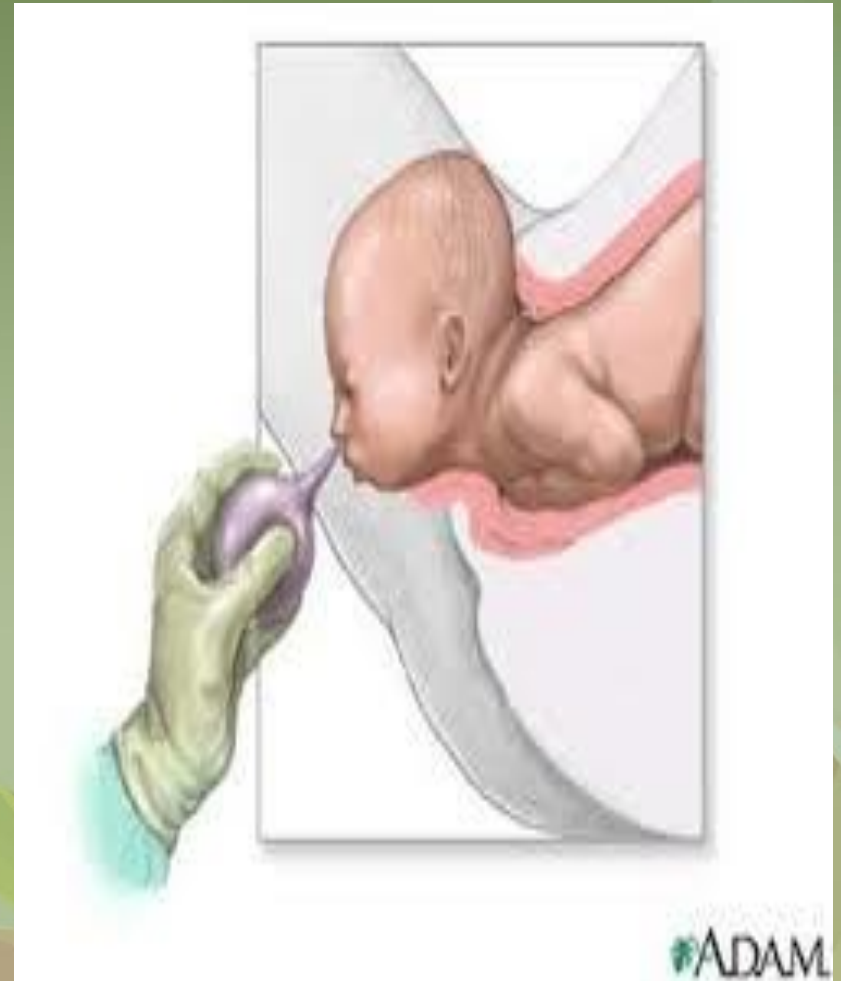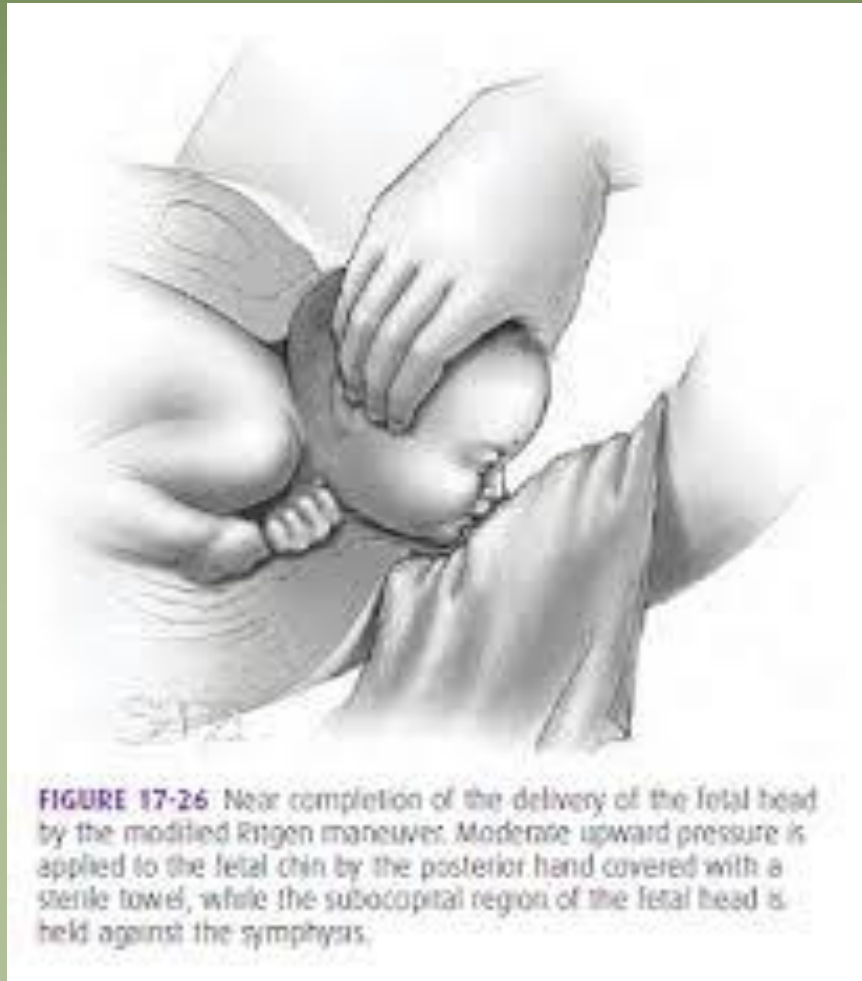
□ Care following delivery of the head:

— Immediately following delivery of the head, the mucus and blood in mouth and pharynx are to be wiped with sterile gauze piece on a little finger. Alternatively, mechanical or electrical sucker may be used. This simple procedure prevents the serious consequence of mucus blocking the air passage during vigorous inspiratory efforts.

— The eyelids are then wiped with sterile dry cotton swabs.

— The neck is then palpated to exclude the presence of any loop of cord.

# Immediate care of new born



# Cont...

- PREVENTION OF PERINEAL LACERATION:  
More attention should be paid not to the perineum but to the controlled delivery of the head.
- Delivery by early extension is to be avoided.
  - Spontaneous forcible delivery of the head is to be avoided.
- To deliver the head in between contractions.
- To perform timely episiotomy (when indicated).
- To take care during delivery of the shoulders as the wider bisacromial diameter (12 cm) emerges out of the introitus.

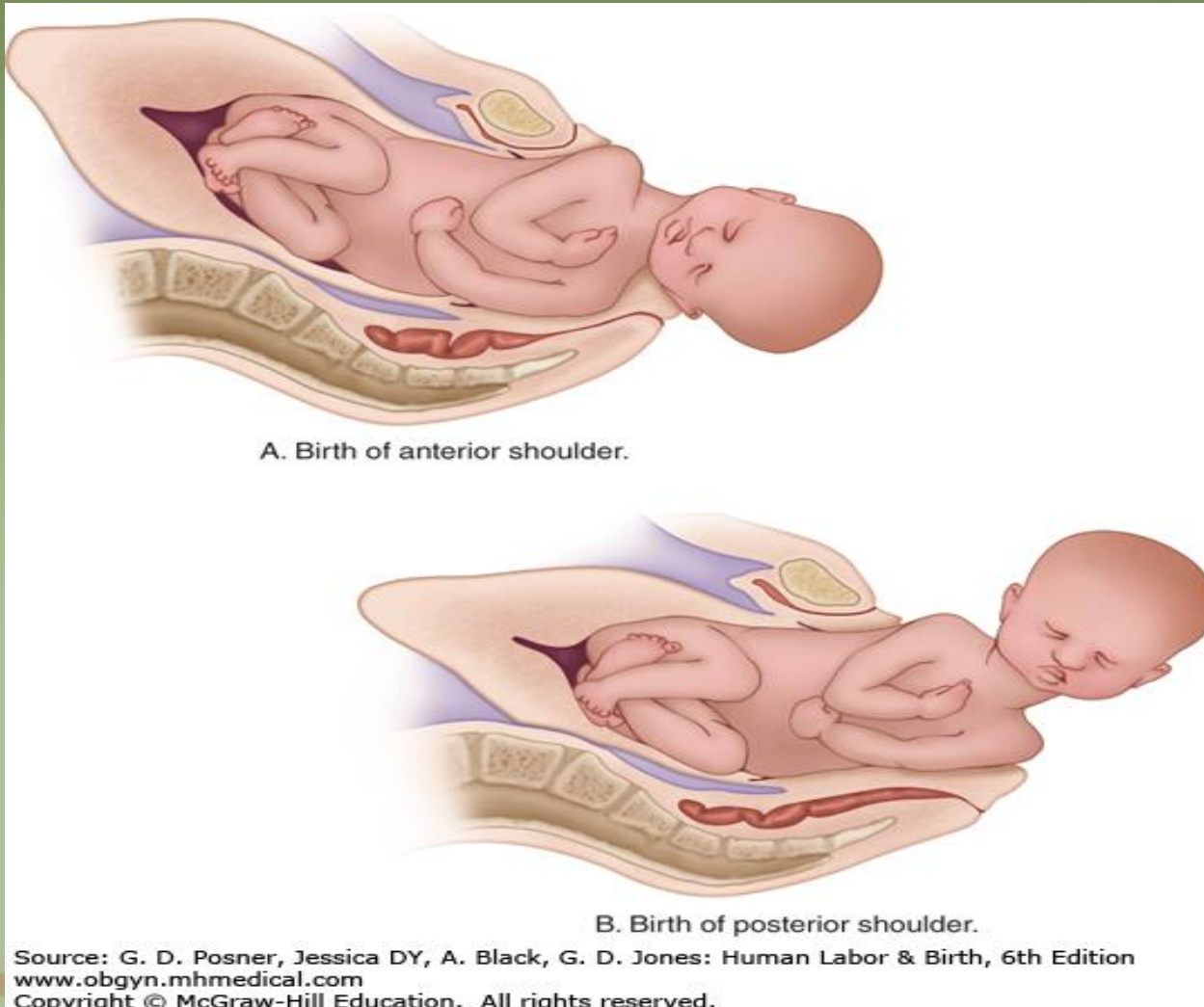


# Cont...

□ Delivery of the shoulders: Not to be hasty in delivery of the shoulders. Wait for the uterine contractions to come and for the movements of restitution and external rotation of the head to occur.

During the next contraction, the anterior shoulder is born behind the symphysis. If there is delay, the head is grasped by both hands and is gently drawn posteriorly until the anterior shoulder is released from under the pubis. By drawing the head in upward direction, the posterior shoulder is delivered out of the perineum. Traction on the head should be gentle to avoid excessive stretching of the neck causing injury to the brachial plexus, hematoma of the neck or fracture of the clavicle.

# DELIVERY OF SHOULDERS



# Cont...

□ Delivery of the trunk: After the delivery of the shoulders, the fore finger of each hand are inserted under the axillae and the trunk is delivered gently by lateral flexion.

## IMMEDIATE CARE OF THE NEWBORN:

□ Soon after the delivery of the baby, it should be placed on a tray covered with clean dry linen with the head slightly downward ( $15^{\circ}$ ). It facilitates drainage of the mucus accumulated in the tracheobronchial tree by gravity. The tray is placed between the legs of the mother and should be at a lower level than the uterus to facilitate gravitation of blood from the placenta to the infant.

# Cont...

- Air passage (oropharynx) should be cleared of mucus and liquor by gentle suction.

- Apgar rating at 1 minute and at 5 minutes is to be recorded.

- Clamping and ligature of the cord:

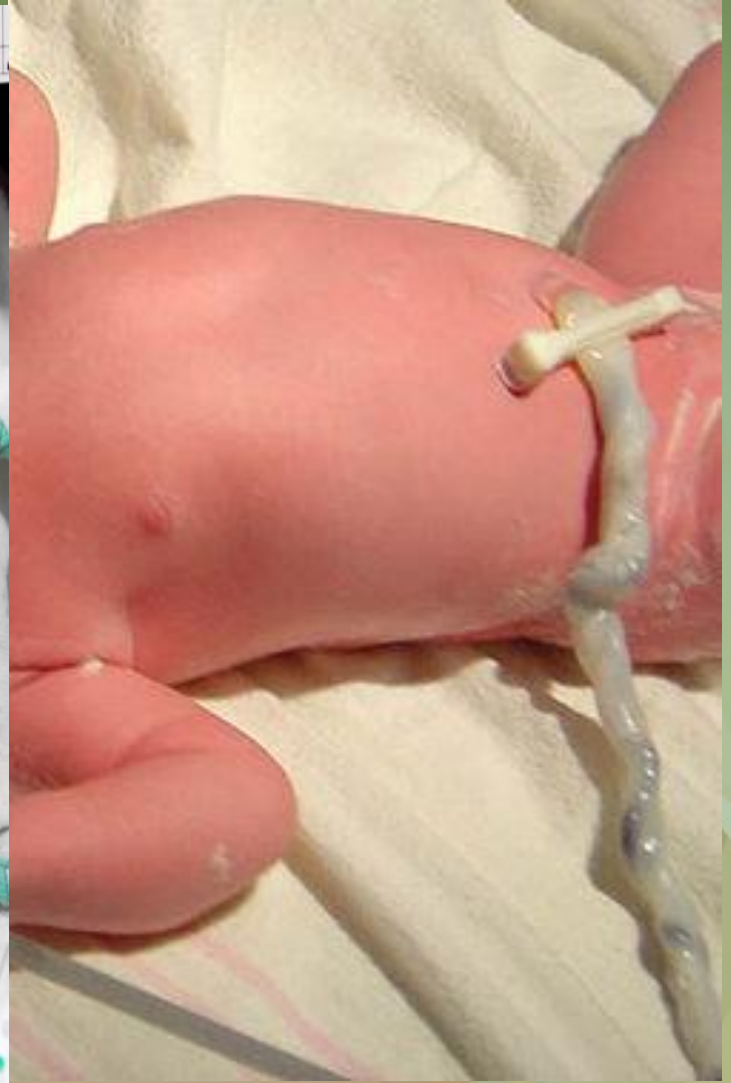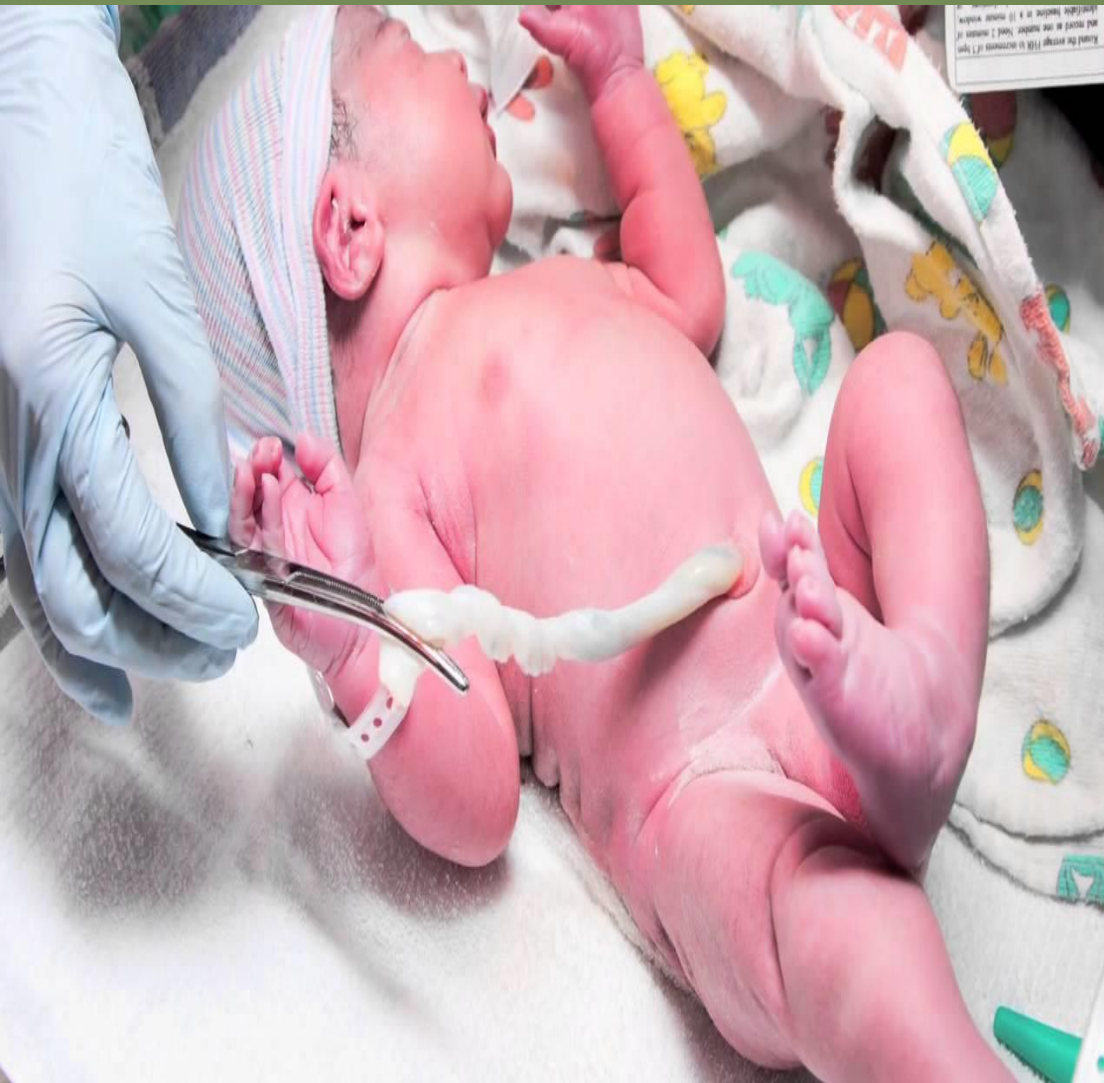The cord is clamped by two Kocher's forceps, the near one is placed 5 cm away from the umbilicus and is cut in between. cord ligature is applied 2.5 cm away from the navel. Presence of any abnormality in cord vessels (single umbilical artery) is to be noted. The cut end is then covered with sterile gauze piece after making sure that there is no bleeding.

# Cont...

Delay in clamping for 2–3 minutes or till cessation of the cord pulsation facilitates transfer of 80–100 mL blood from the compressed placenta to a baby when placed below the level of uterus. This is beneficial to a mature baby but may be deleterious to a preterm or a low birthweight baby due to hypervolemia and hyperbilirubinemia. But early clamping should be done in cases of Rh-incompatibility (to prevent antibody transfer from the mother to the baby)



# CORD LIGATION



# MANAGEMENT OF THE THIRD STAGE

Third stage is the most crucial stage of labor. Previously uneventful first and second stage can become abnormal within a minute with disastrous consequences.

The principles underlying the management of third stage are to ensure strict vigilance and to follow the management guidelines strictly in practice so as to prevent the complications, the important one being postpartum hemorrhage.

**STEPS OF MANAGEMENT:** Two methods of management are currently in practice.

- ☐ Expectant management
- ☐ Active management (preferred)

# Expectant management (traditional)

In this management, the placental separation and its descent into the vagina are allowed to occur spontaneously. Minimal assistance may be given for the placental expulsion if it needed.

- ☐ Constant watch is mandatory and the patient should not be left alone.
- ☐ A hand is placed over the fundus—
  - (a) to recognize the signs of separation of placenta,
  - (b) to note the state of uterine activity—contraction and relaxation.

# Cont...

Placenta is separated within minutes following the birth of the baby. A watchful expectancy can be extended up to 15–20 minutes. In some institutions, “no touch” or “hands off” policy is employed. The patient is expected to expel the placenta within 20 minutes with the aid of gravity.

□ Expulsion of the placenta: Only when the features of placental separation and its descent into the lower segment are confirmed, the patient is asked to bear down simultaneously with the hardening of the uterus. The raised intra-abdominal pressure is often adequate to expel the placenta.

# Cont....

If the patient fails to expel, one can wait safely up to 10 minutes if there is no bleeding. As soon as the placenta passes through the introitus, it is grasped by the hands and twisted round and round with gentle traction so that the membranes are stripped intact. Gentleness, patience and care are prerequisites for complete delivery of the membranes.

If the spontaneous expulsion fails, any one of the following methods can be used to expedite expulsion:



# ASSISTED EXPULSION

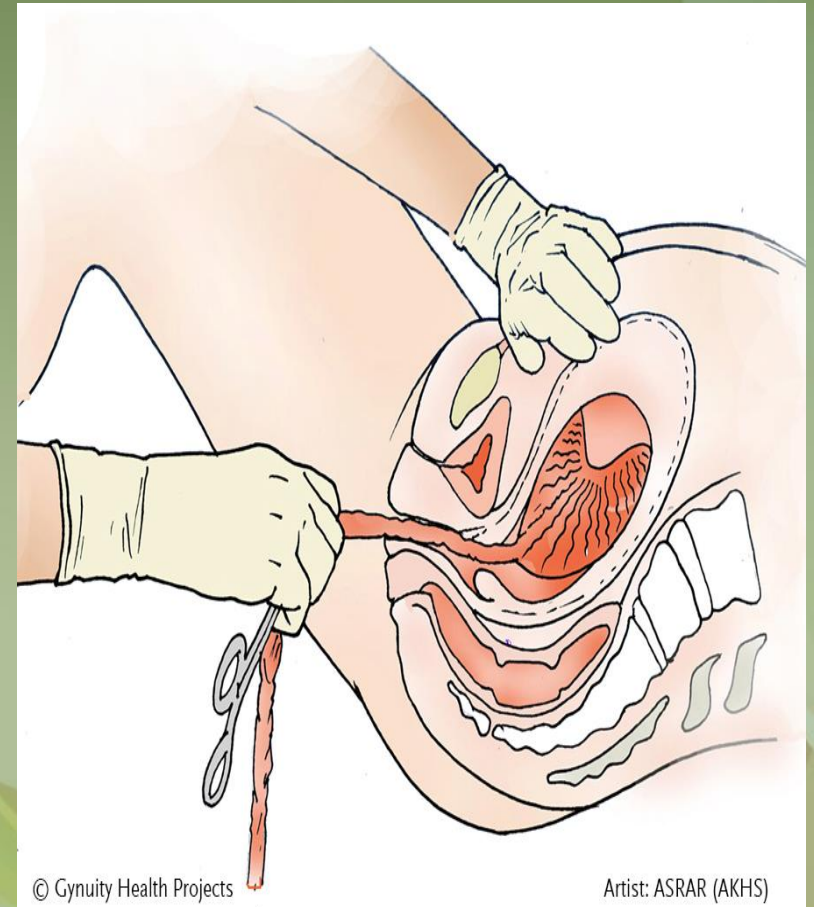
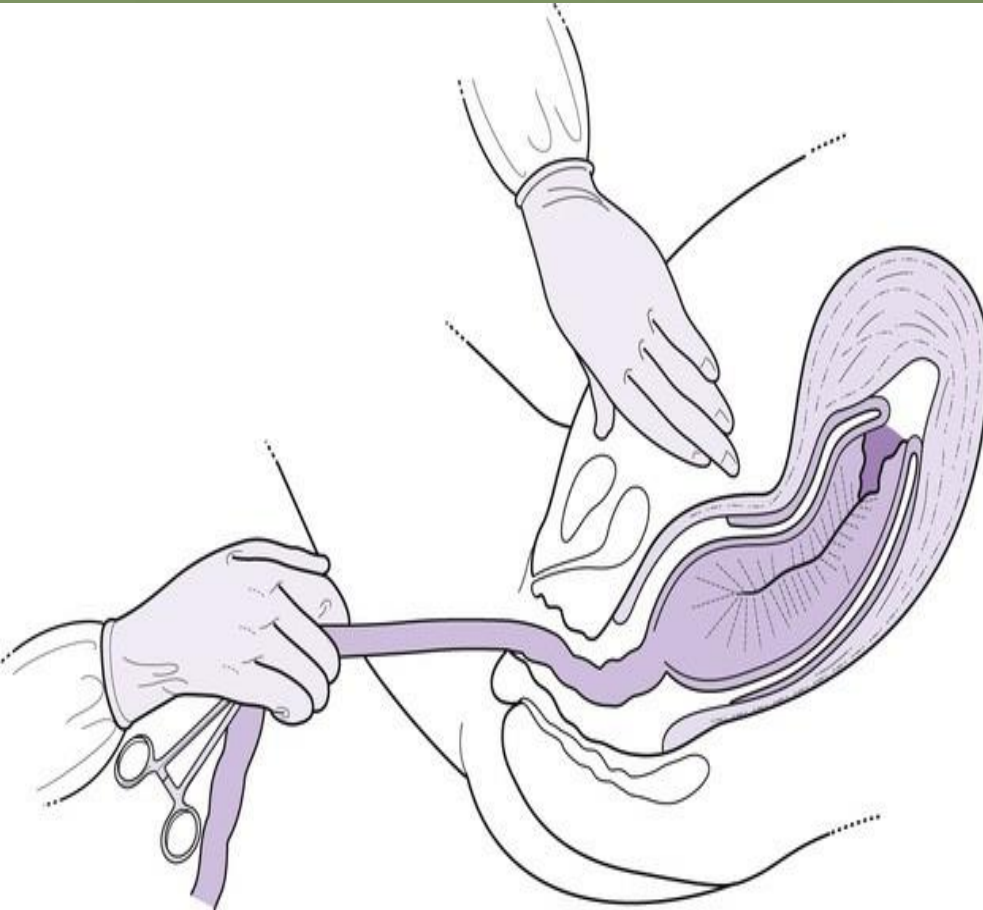
- (a) Controlled cord traction (modified Brandt-Andrews method)—The palmar surface of the fingers of the left hand is placed (above the symphysis pubis) approximately at the junction of upper and lower uterine segment. The body of the uterus is pushed upward and backward, toward the umbilicus while by the right hand steady tension (but not too strong traction) is given in downward and backward direction holding the clamp until the placenta comes outside the introitus.
- (b) Fundal pressure—The fundus is pushed downward and backward after placing four fingers behind the fundus and the thumb in front using the uterus as a sort of piston.

# Cont...

Pressure must be given only when the uterus becomes hard. The pressure is to be withdrawn as soon as the placenta passes through the introitus. The sterile gloved hand should be introduced, and the placenta is to be grasped and extracted.

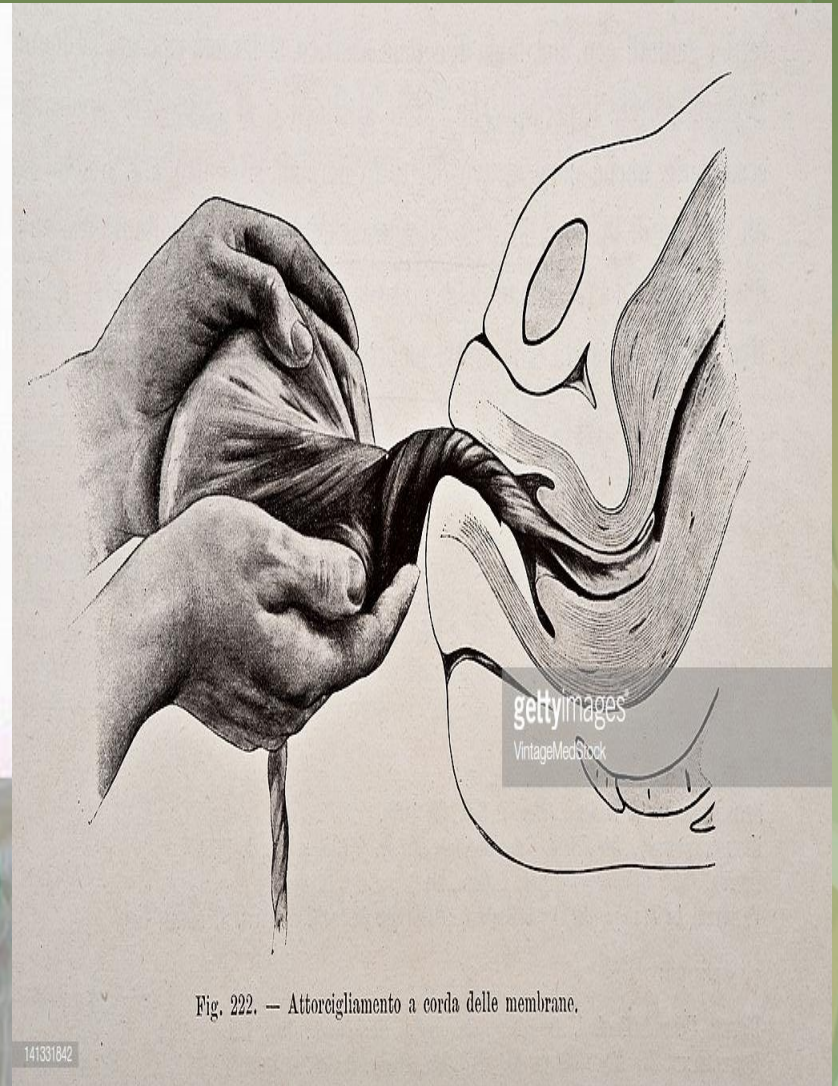
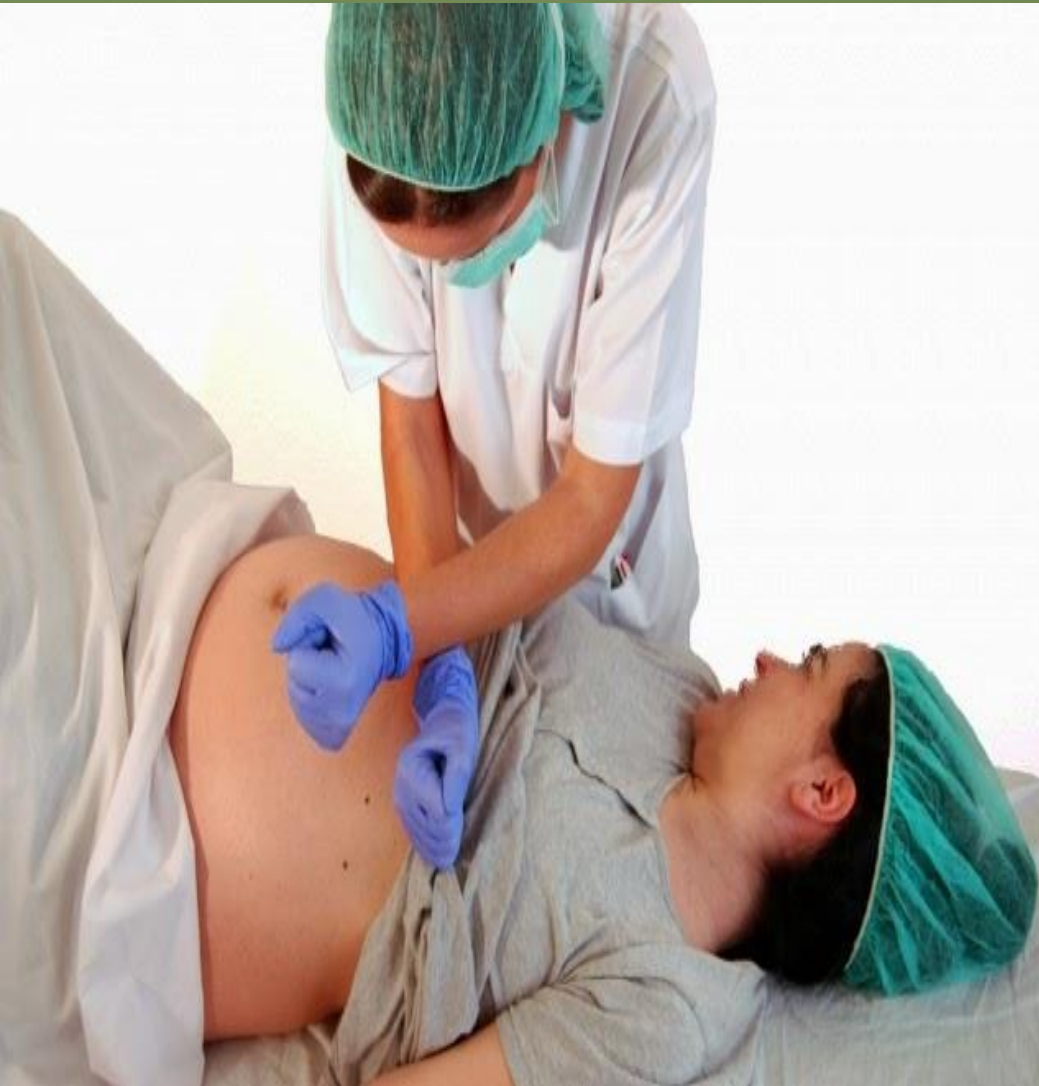— The uterus is massaged to make it hard, which facilitates expulsion of retained clots if any. Injection of oxytocin (5–10 units) IV slowly/IM or methergine 0.2 mg is given intramuscularly. Oxytocin is more stable and has lesser side effects compared to ergometrine (nausea, vomiting, rise of BP).

# CONTROLLED CORD TRACTION



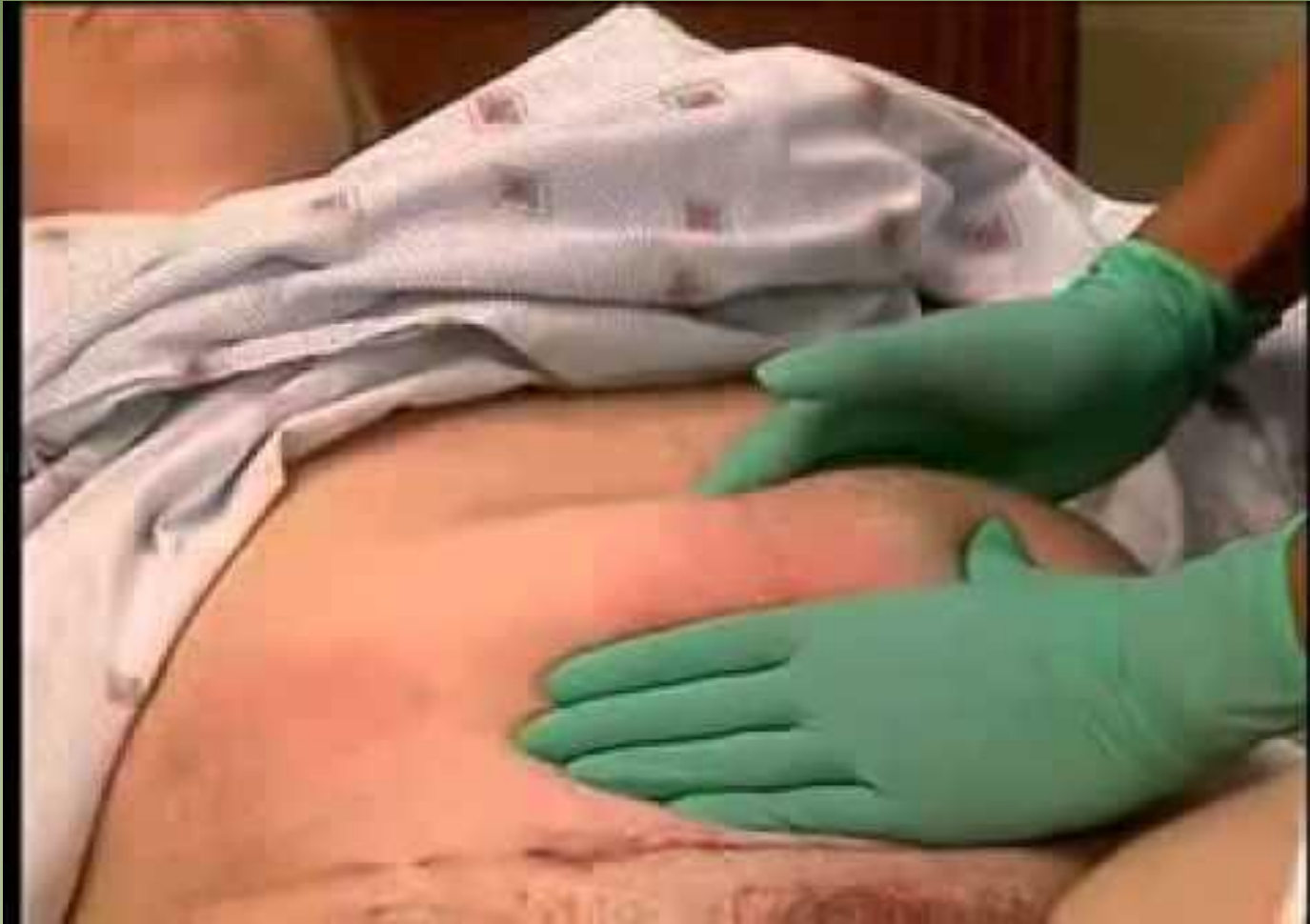

# FUNDAL PRESSURE



141331842

# FUNDAL MASSAGE

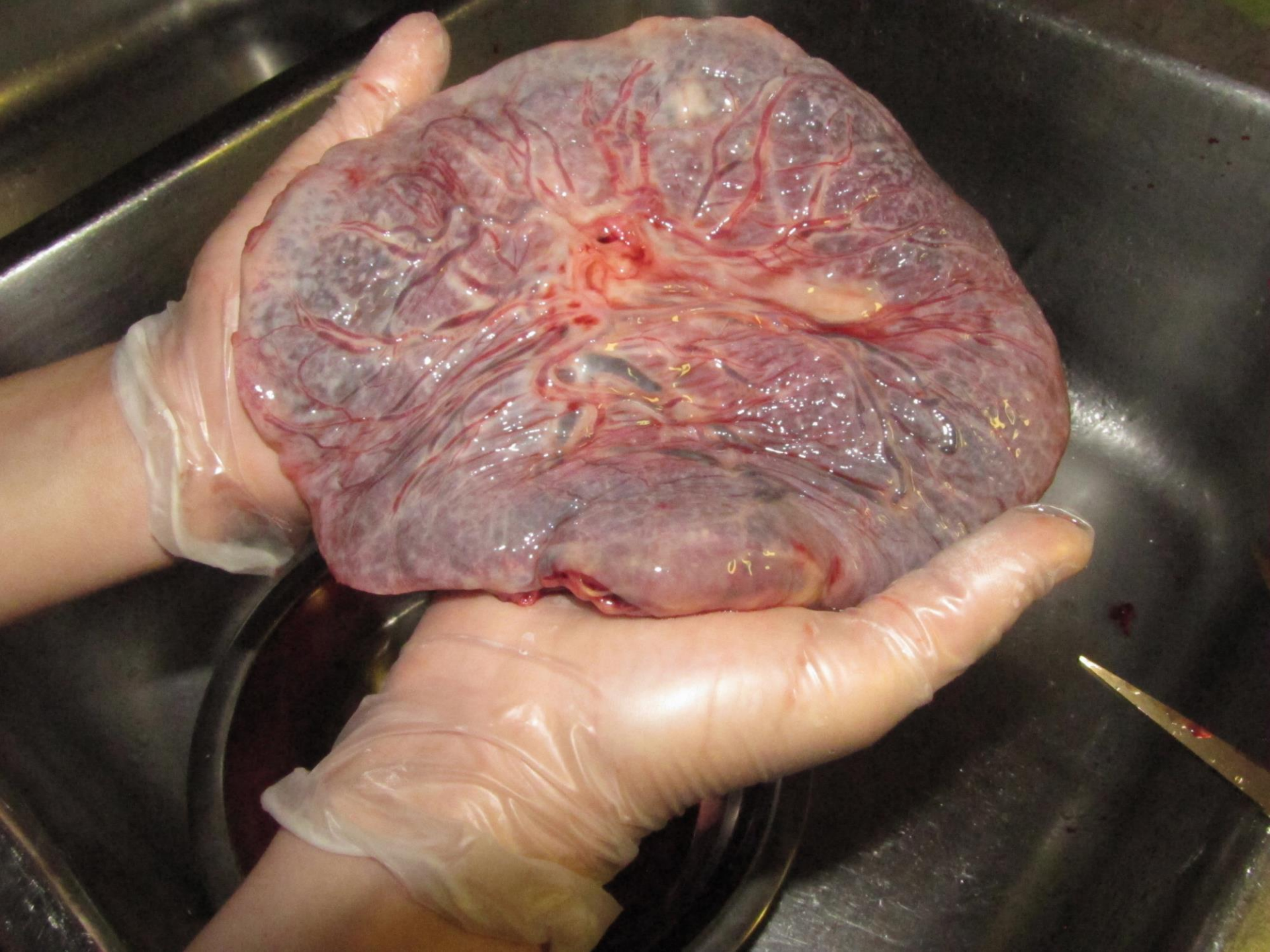



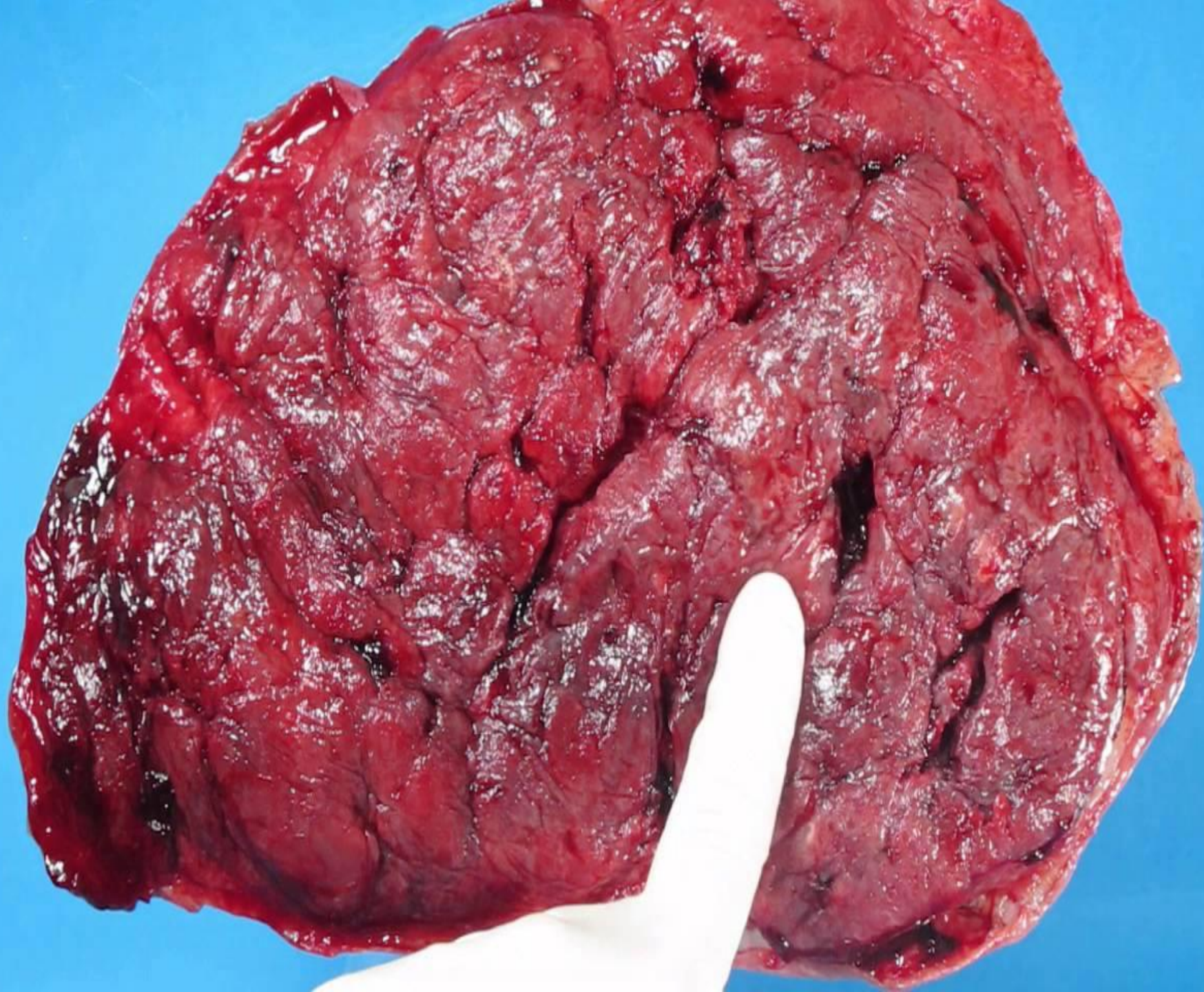# Cont...

— Examination of the placenta membranes and cord: The placenta is placed on a tray and is washed out in running tap water to remove the blood and clots. The maternal surface is first inspected for its completeness and anomalies. The maternal surface is covered with grayish decidua (spongy layer of the decidua basalis).

The membranes—chorion and amnion are to be examined carefully for completeness. The amnion is shiny but the chorion is shaggy. The cut end of the cord is inspected for number of blood vessels. Normally, there are two umbilical arteries and one umbilical vein.







# Cont...

— Vulva, vagina and perineum are inspected carefully for injuries and to be repaired, if any. The episiotomy wound is now sutured. The vulva and adjoining part are cleaned with cotton swabs soaked in antiseptic solution. A sterile pad is placed over the vulva.

## ACTIVE MANAGEMENT OF THIRD STAGE OF LABOR (AMTSL)

The underlying principle in active management is to excite powerful uterine contractions within 1 minute of delivery of the baby (WHO) by giving parenteral oxytocic. This facilitates not only early separation of the placenta but also produces effective uterine contractions following its separation.



# Cont...

The advantages are—(a) to minimize blood loss in third stage (b) to shorten the duration of third stage to half.

The only disadvantage is slight increased incidence of retained placenta (1–2%) and consequent increased incidence of manual removal. Of course, accidental administration during delivery of the first baby in undiagnosed twins produces grave danger to the unborn second baby caused by asphyxia due to tetanic contraction of the uterus. Thus, it is imperative to limit its use in twins only following delivery of the second baby.



# FOURTH STAGE OF LABOR

Pulse, blood pressure, tone of the uterus (well retracted) and any abnormal vaginal bleeding are to be watched at least for 1 hour after delivery. When fully satisfied that the general condition is good, pulse and blood pressure are steady, the uterus is well retracted and there is no abnormal vaginal bleeding, the patient is sent to the ward.

# MECHANISM OF NORMAL LABOR

**DEFINITION:** The series of movements that occur on the head in the process of adaptation during its journey through the pelvis is called mechanism of labor.

**MECHANISM:** In normal labor, the head enters the brim more commonly through the available transverse diameter (70%) and to a lesser extent through one of the oblique diameters. Accordingly, the position is either occipitolateral or oblique occipitoanterior. Left occipitoanterior is little more common than right occipitoanterior. The engaging anteroposterior diameter of the head is either suboccipitobregmatic 9.5 cm (3 3/4") or in slight deflexion—the suboccipitofrontal 10 cm (4").

# Cont...

The engaging transverse diameter is biparietal 9.5 cm (3.74"). As the occipitolateral position is the most common, the mechanism of labor in such position will be described. The principal movements are:

- (1) engagement,
- (2) descent,
- (3) flexion,
- (4) internal rotation,
- (5) crowning,
- (6) extension,
- (7) restitution,
- (8) external rotation, and
- (9) expulsion of the trunk.

# Cont...

Engagement: Head brim relation prior to the engagement as revealed by imaging studies shows that due to lateral inclination of the head, the sagittal suture does not strictly correspond with the available transverse diameter of the inlet. Instead, it is either deflected anteriorly toward the symphysis pubis or posteriorly toward the sacral promontory. Such deflection of the head in relation to the pelvis is called asynclitism.

When the sagittal suture lies anteriorly, the posterior parietal bone becomes the leading presenting part and is called posterior asynclitism or posterior parietal presentation. This is more frequently found in primigravidae.

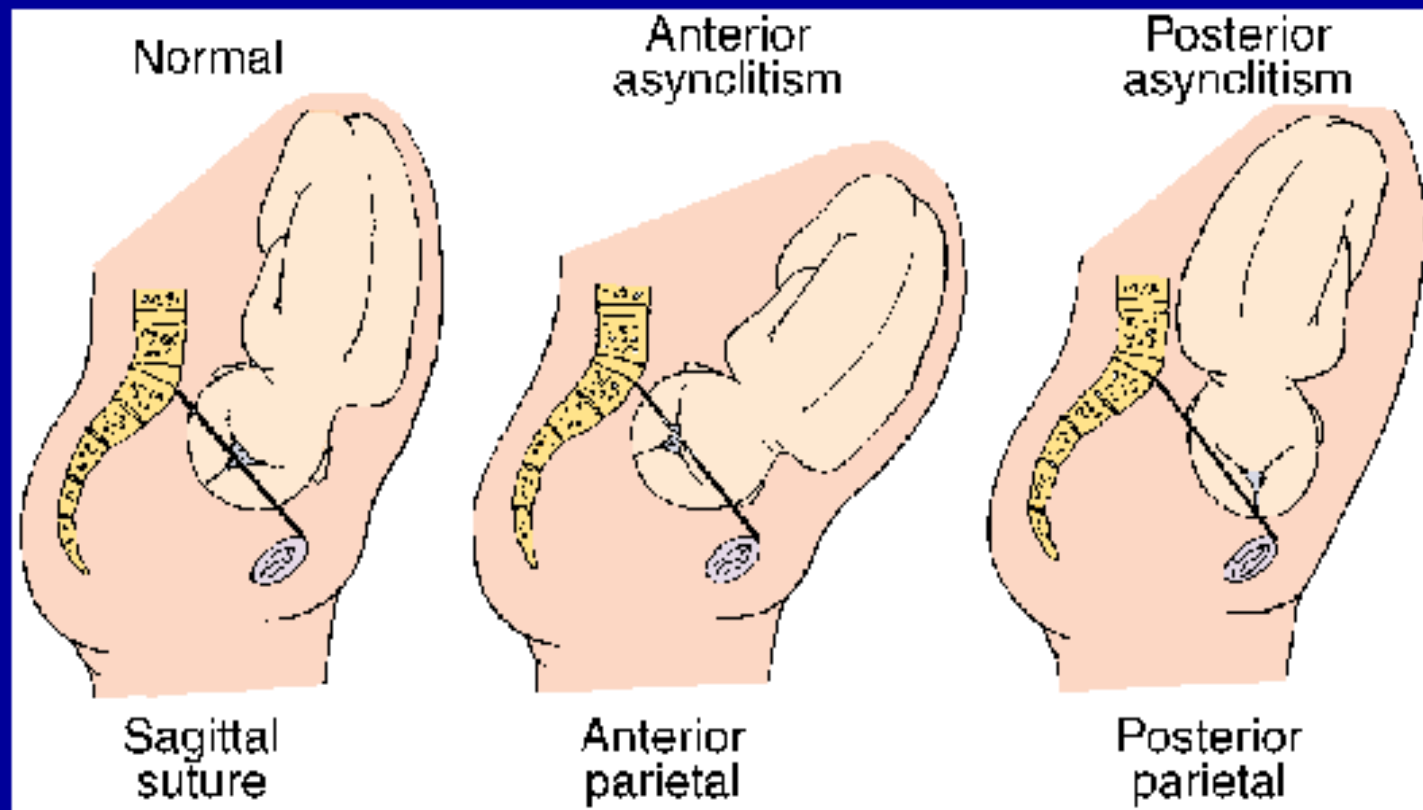
# Cont...

In others, the sagittal suture lies more posteriorly with the result that the anterior parietal bone becomes the leading presenting part and is then called anterior parietal presentation or anterior asynclitism. It is more commonly found in multiparae. Mild degrees of asynclitism are common but severe degrees indicate cephalopelvic disproportion.

In primigravidae, engagement occurs in a significant number of cases before the onset of labor while in multiparae, the same may occur in late first stage with rupture of the membranes.



# Asynclitism



# Cont...

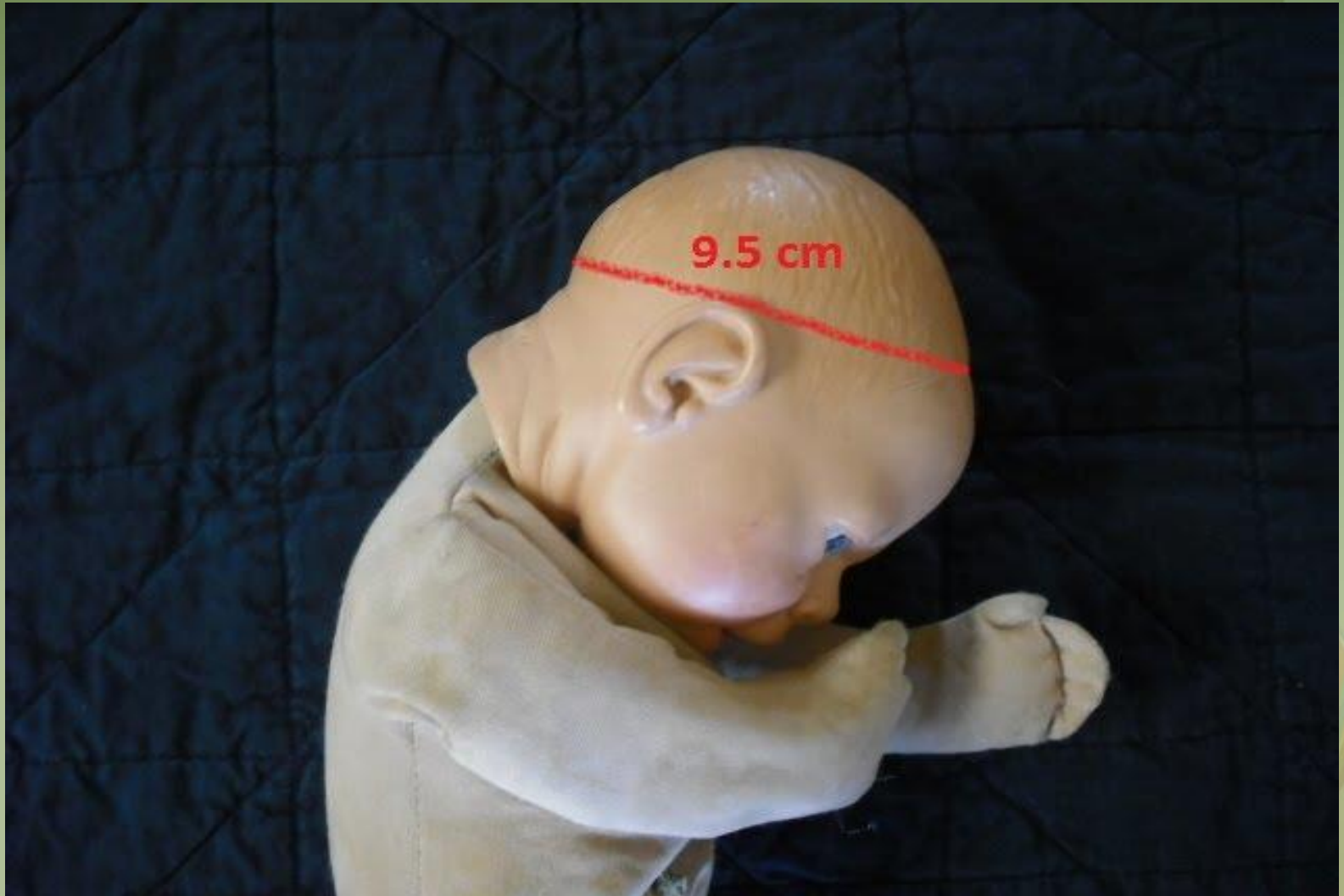Descent: descent is a continuous process. It is slow or insignificant in first stage but pronounced in second stage. It is completed with the expulsion of the fetus. In primigravidae, with prior engagement of the head, there is practically no descent in first stage; while in multiparae, descent starts with engagement. Head is expected to reach the pelvic floor by the time the cervix is fully dilated. Factors facilitating descent are—

- (1) uterine contraction and retraction,
- (2) bearing down efforts

# Cont...

Flexion: While some degree of flexion of the head is noticeable at the beginning of labor but complete flexion is rather uncommon. As the head meets the resistance of the birth canal during descent, full flexion is achieved. Thus, if the pelvis is adequate, flexion is achieved either due to the resistance offered by the unfolding cervix, the walls of the pelvis or by the pelvic floor. Flexion is essential for descent, since it reduces the shape and size of the plane of the advancing diameter of the head.

# FLEXION



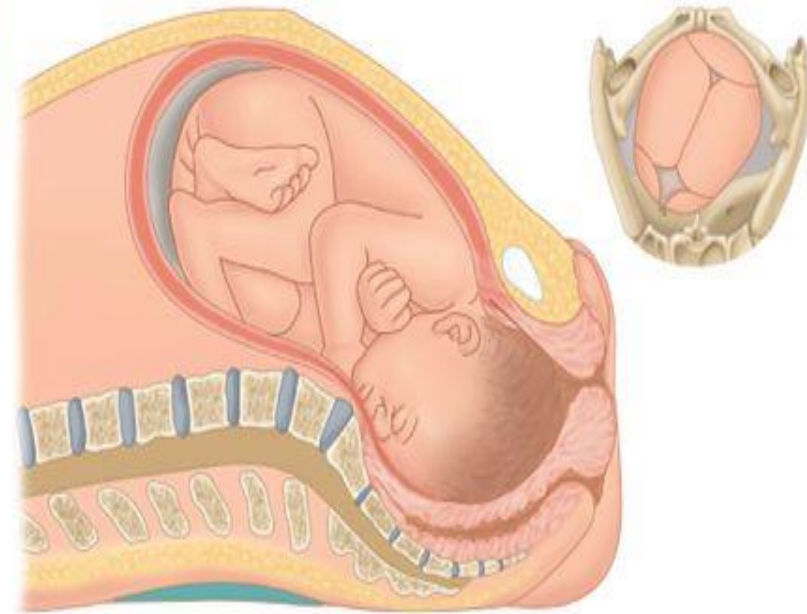
# Cont...

Internal rotation: It is a movement of great importance without which there will be no further descent. The mechanism of internal rotation is very complex. In occipitolateral position, there will be anterior rotation by two-eighths of a circle of the occiput whereas in oblique anterior position, rotation will be one-eighth of a circle forward, placing the occiput behind the symphysis pubis. There is always an accompanying movement of descent with internal rotation. Thus, prerequisites of anterior internal rotation of the head are well-flexed head, efficient uterine contraction, favorable shape at the midpelvic plane, and tone of the levator ani muscles.

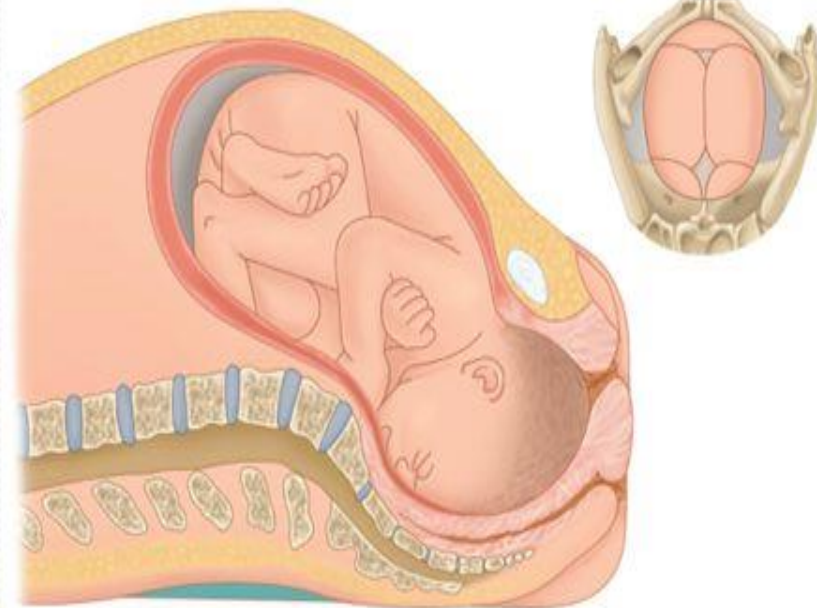


# INTERNAL ROTATION

- This movement consists of a turning of the head in such a manner that the occiput gradually moves toward the symphysis pubis anteriorly from its original position.



3. Further descent, internal rotation

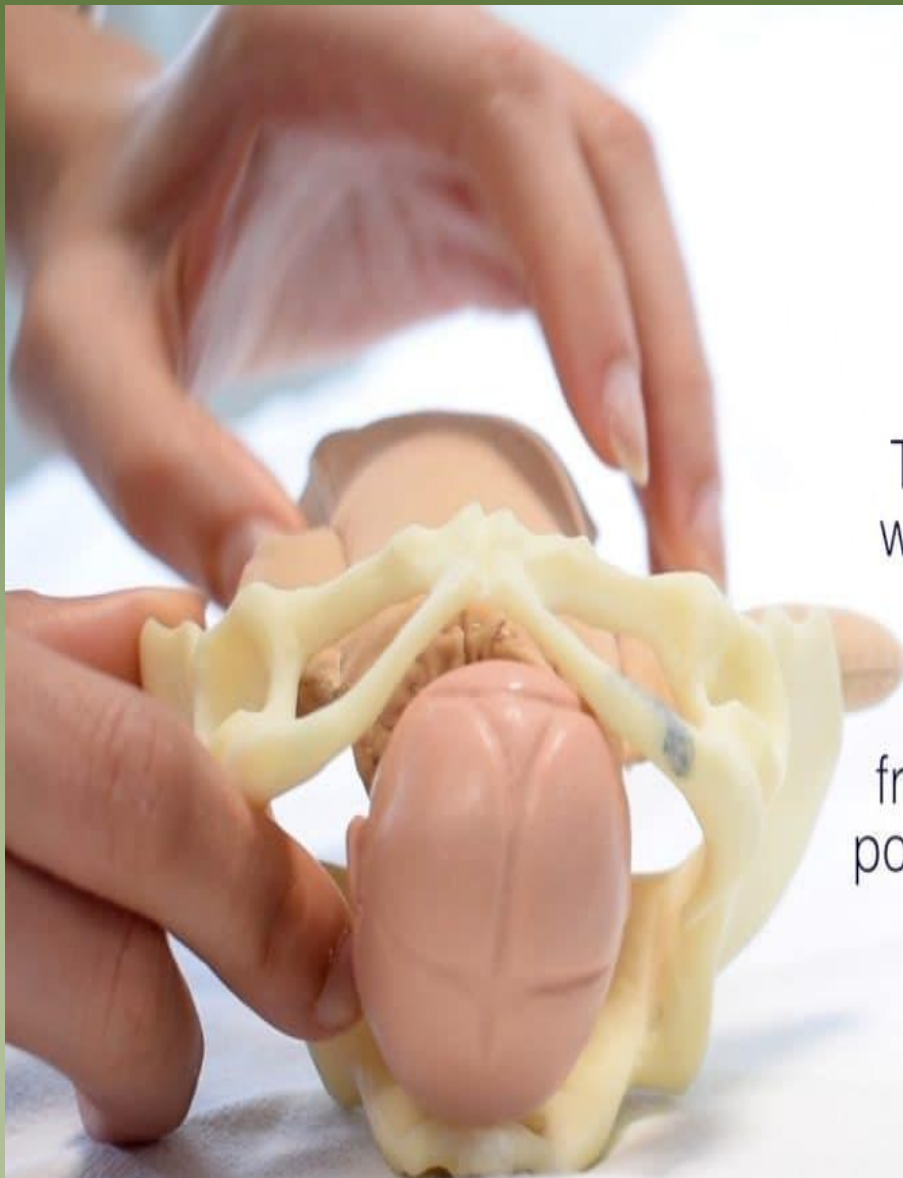


4. Complete rotation, beginning extension

# INTERNAL ROTATION

The pelvic floor has a gutter shape, with a forward and downward slope.

This allows the head to rotate from a left or right occipito-transverse position to an occipito-anterior position.



# Cont...

Torsion of the neck: Torsion of the neck is an inevitable phenomenon during internal rotation of the head. If the shoulders remain in the anteroposterior diameter, the neck has to sustain a torsion of two-eighths of a circle corresponding with the same degree of anterior rotation of the occiput. But the neck fails to withstand such major degree of torsion and as such there will be some amount of simultaneous rotation of the shoulders in the same direction to the extent of one-eighth of a circle placing the shoulders to lie in the oblique diameter with one-eighth of torsion still left behind.

# Cont...

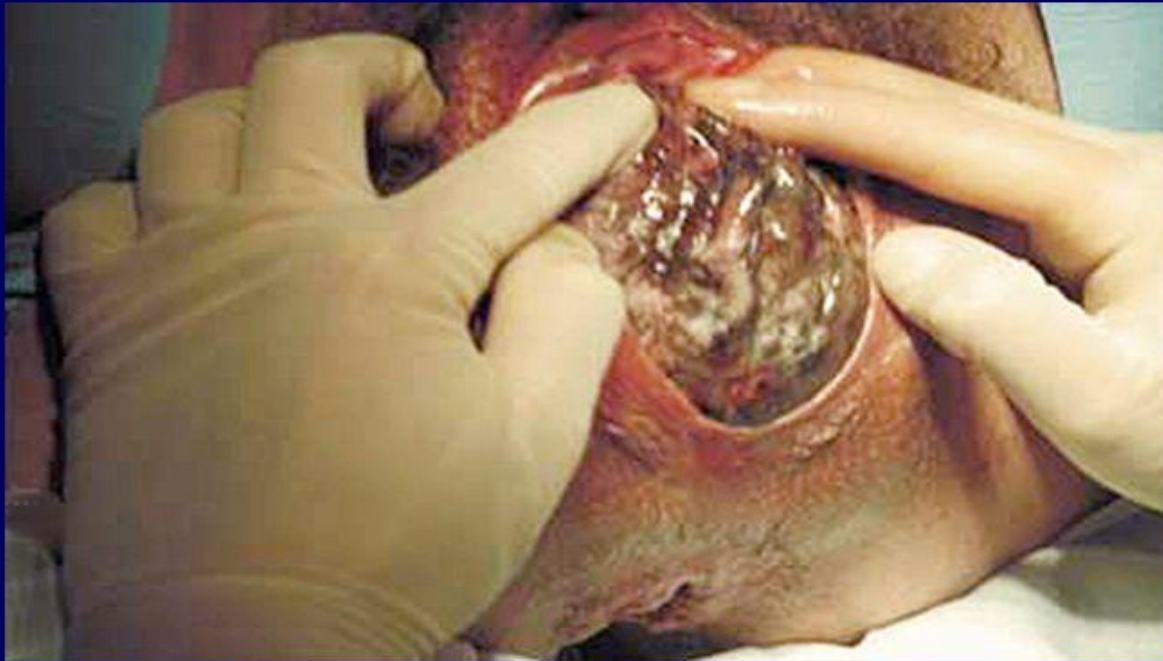In oblique occipitoanterior position, there is no movement of the shoulders from the oblique diameter as the neck sustains a torsion of only one-eighth of a circle.

**Crowning:** After internal rotation of the head, further descent occurs until the subocciput lies underneath the pubic arch. At this stage, the maximum diameter of the head (biparietal diameter) stretches the vulval outlet without any recession of the head even after the contraction is over— called “crowning of the head”.



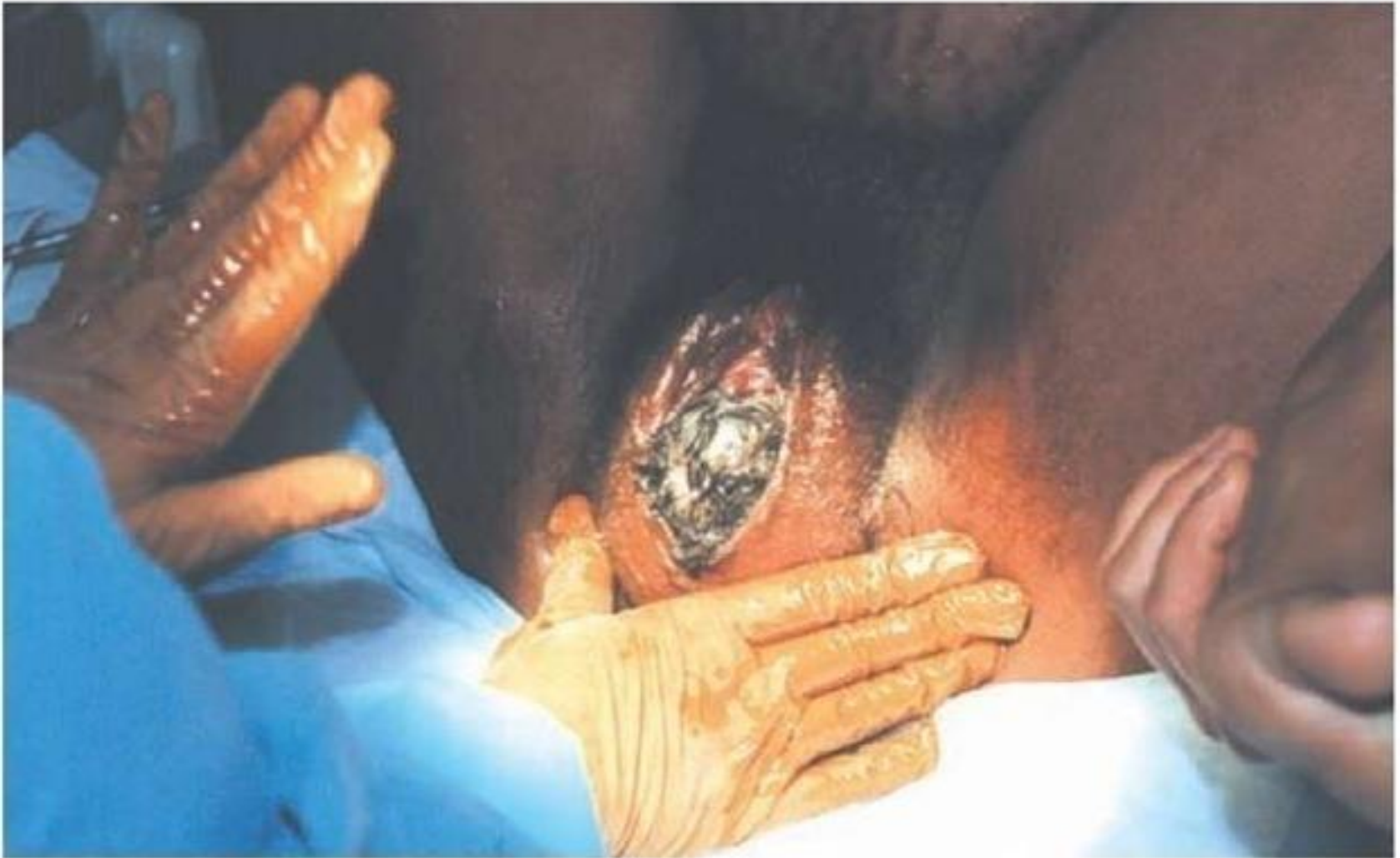# CROWNING

Crowning...





# Cont...

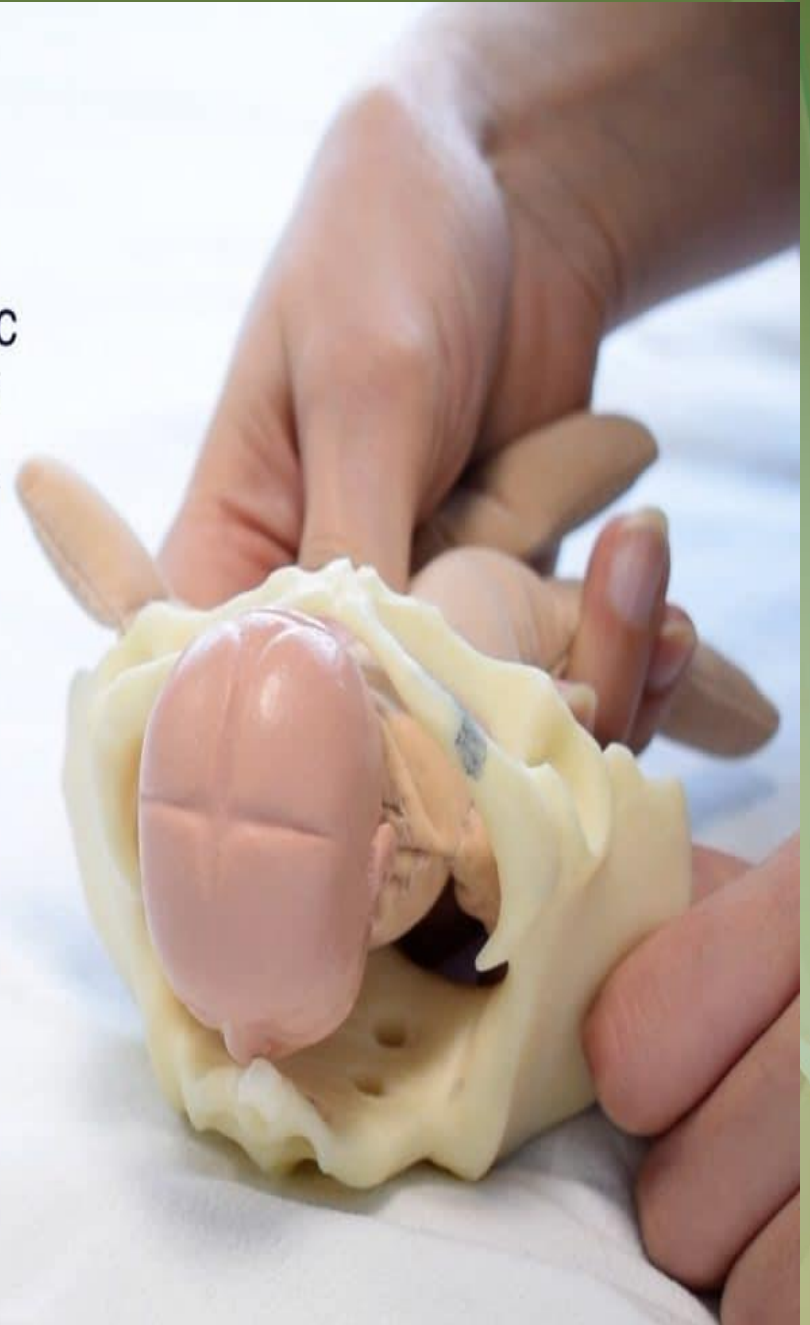
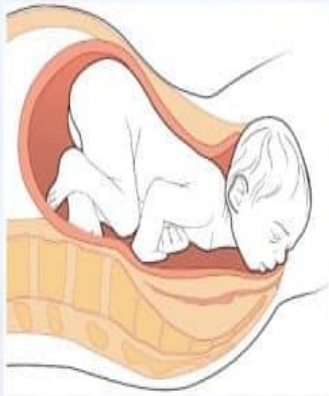
# Cont...

Extension: Delivery of the head takes place by extension through “couple of force” theory. The driving force pushes the head in a downward direction while the pelvic floor offers a resistance in the upward and forward direction. The downward and upward forces neutralize and remaining forward thrust helping in extension. The successive parts of the fetal head to be born through the stretched vulval outlet are vertex, brow and face. Immediately following the release of the chin through the anterior margin of the stretched perineum, the head drops down, bringing the chin in close proximity to the maternal anal opening.

# EXTENSION

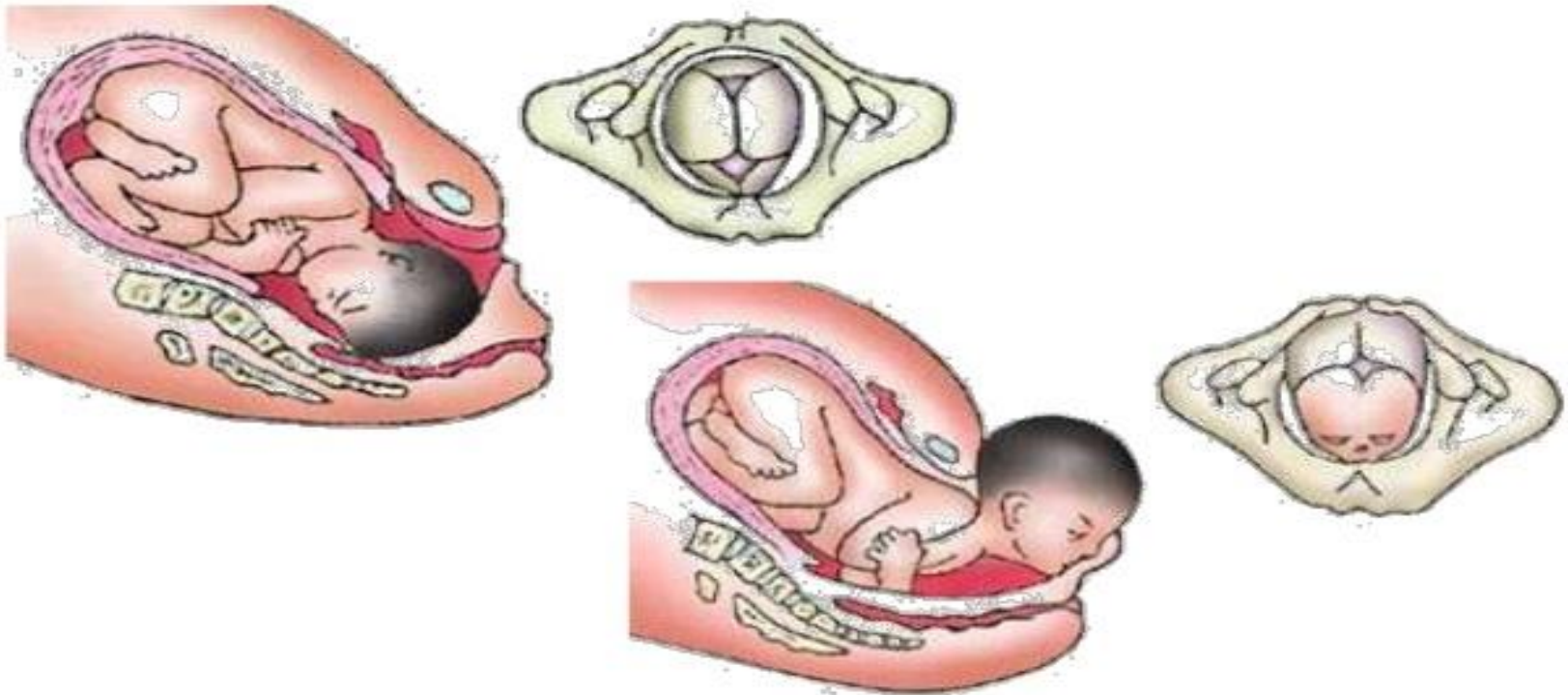
The occiput slips beneath the suprapubic arch as the head extends and the nape of the neck is pivoting against the arch.



# Cont...

## The second stage

### □ Extension





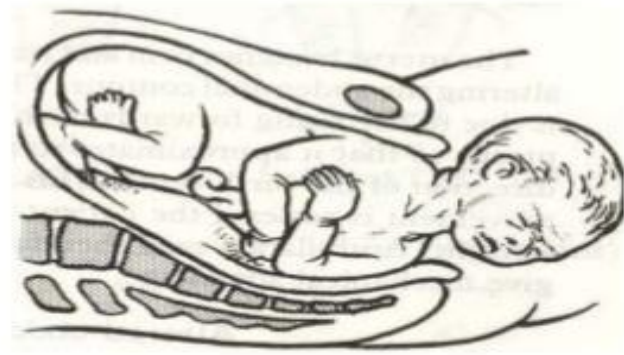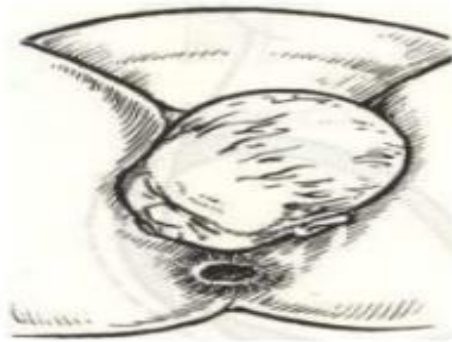
# Cont...

Restitution: It is the visible passive movement of the head due to untwisting of the neck sustained during internal rotation. Movement of restitution occurs rotating the head through one-eighth of a circle in the direction opposite to that of internal rotation. The occiput thus points to the maternal thigh of the corresponding side to which it originally lay.

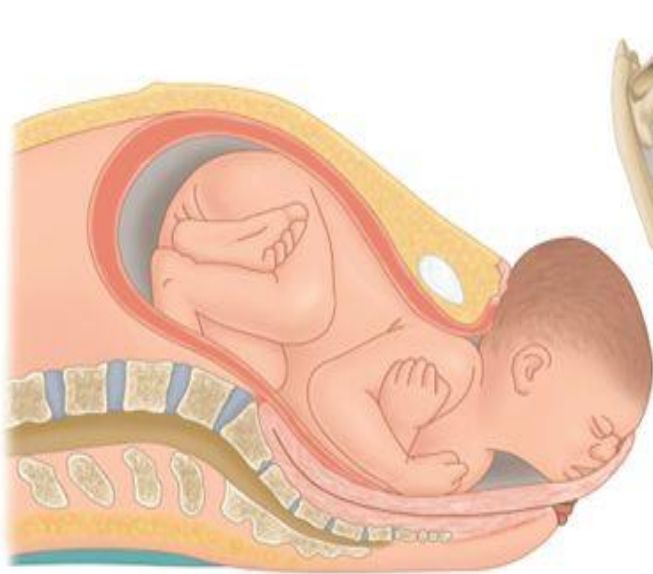

# Cont...

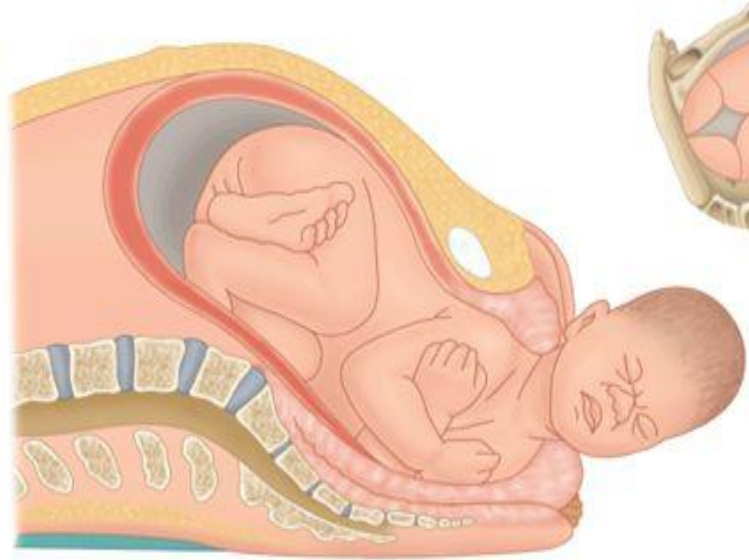
## Restitution



- Head rotates to natural position relative to the shoulders
- This is restitution



5. Complete extension



6. Restitution (external rotation)

- Restitution of the head to the **oblique** position is followed by completion of external rotation **to the transverse position**, a movement that corresponds to rotation of the fetal body, serving to bring its bisacromial diameter into relation **with the anteroposterior diameter of the pelvic outlet**. Thus, one shoulder is anterior behind the symphysis and the other is posterior.

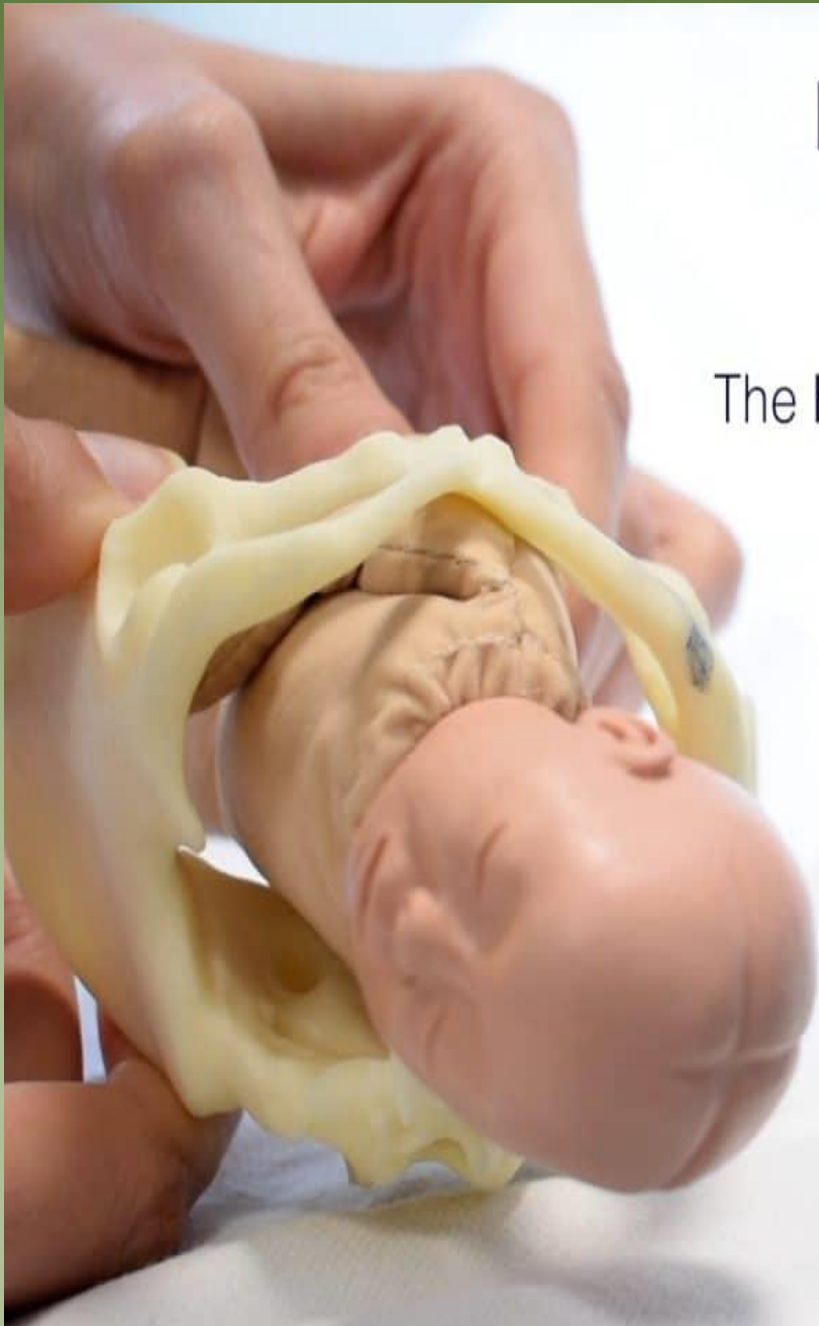# Cont...

External Rotation: It is the movement of rotation of the head visible externally due to internal rotation of the shoulders. As the anterior shoulder rotates toward the symphysis pubis from the oblique diameter, it carries the head in a movement of external rotation through one-eighth of a circle in the same direction as restitution. The shoulders now lie in the anteroposterior diameter. The occiput points directly toward the maternal thigh corresponding to the side to which it originally directed at the time of engagement



# EXTERNAL ROTATION & RESTITUTION

The head externally rotates to face the right or left medial-thigh of the mother.



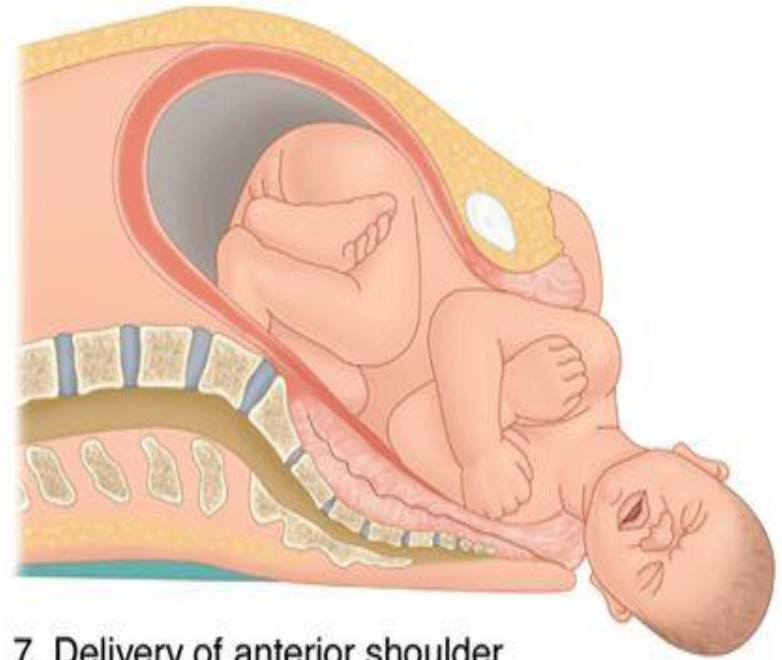
# Cont...

Birth of Shoulders and Trunk : After the shoulders are positioned in anteroposterior diameter of the outlet, further descent takes place until the anterior shoulder escapes below the symphysis pubis first. By a movement of lateral flexion of the spine, the posterior shoulder sweeps over the perineum. Rest of the trunk is then expelled out by lateral flexion.

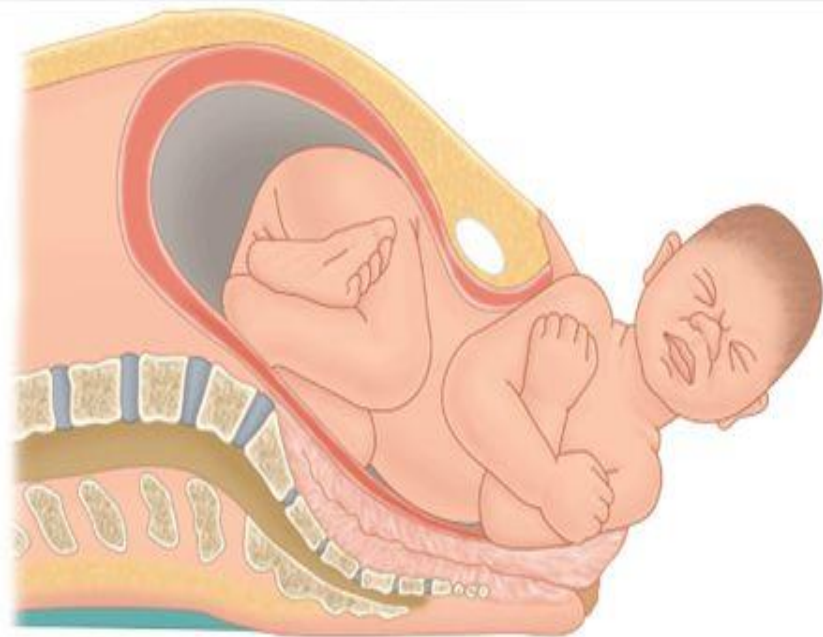


# EXPULSION

- Almost immediately after external rotation, the anterior shoulder appears under the symphysis pubis, and the perineum soon becomes distended by the posterior shoulder. After delivery of the shoulders, the rest of the body quickly passes.

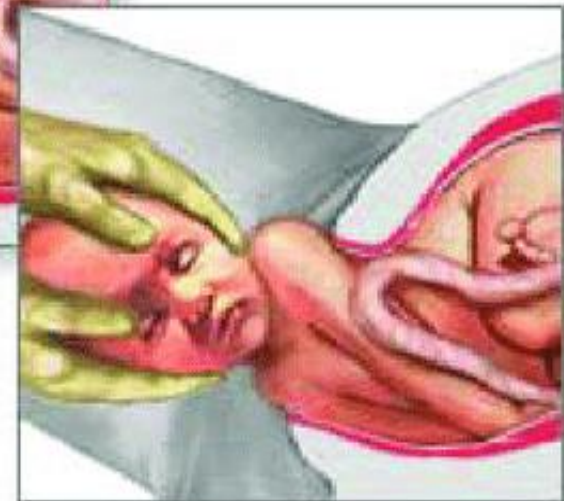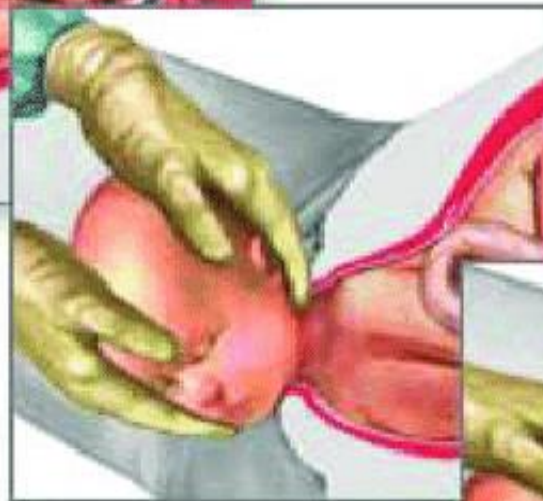
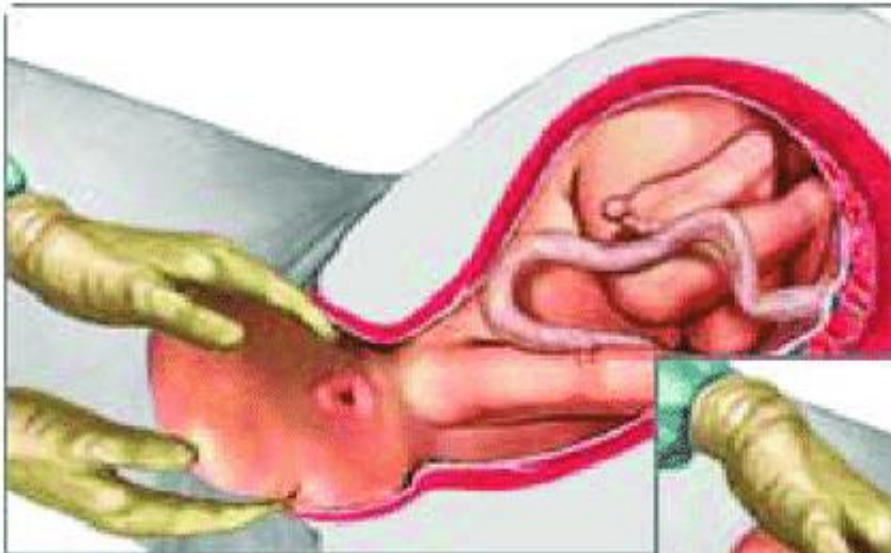


7. Delivery of anterior shoulder



8. Delivery of posterior shoulder

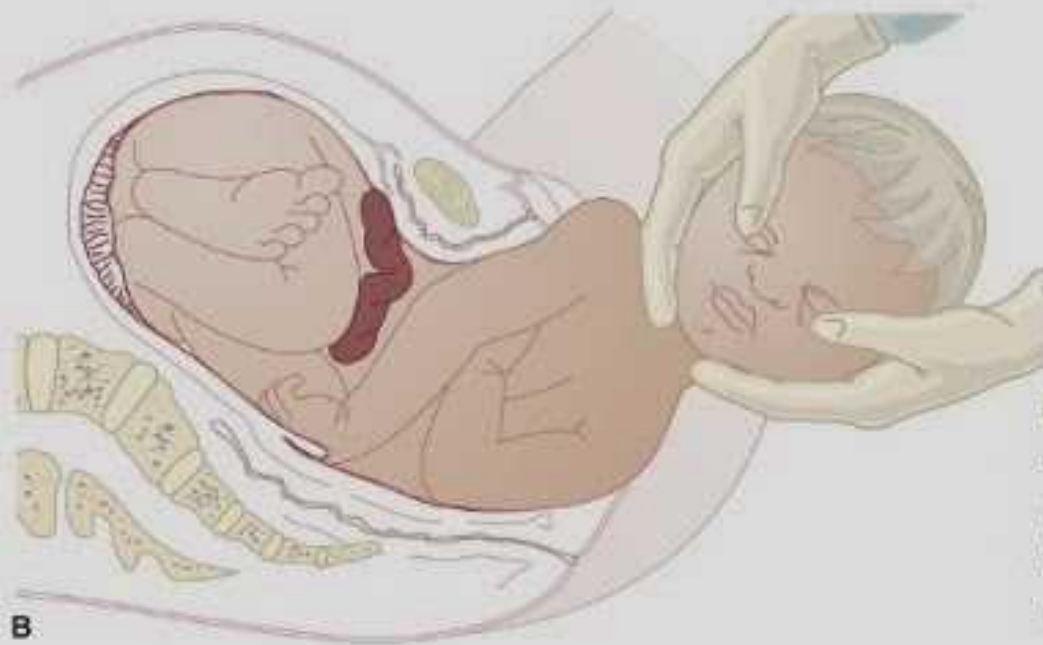## Vaginal birth



As the baby's head is delivered, support it with your hands. It will naturally turn to one side.



**A**

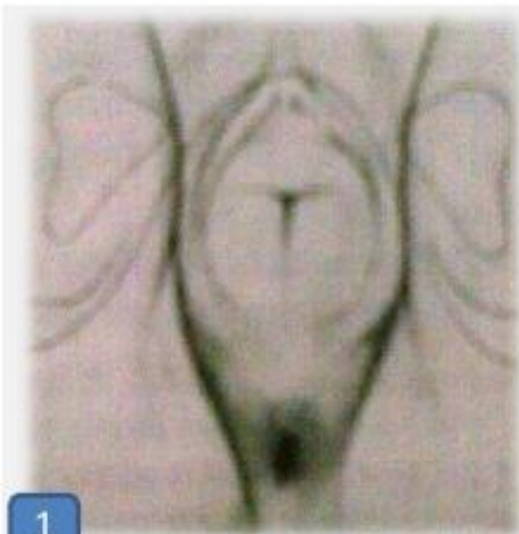


**B**

Delivery of the shoulders. **A:** Gentle downward traction on the head is applied to deliver the anterior shoulder. **B:** Gentle upward traction is used to deliver the posterior shoulder.

[muhadharaty.com](http://muhadharaty.com)





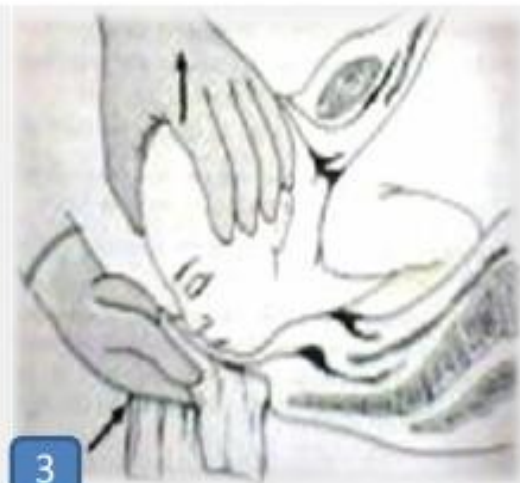1

Crowning of the Head



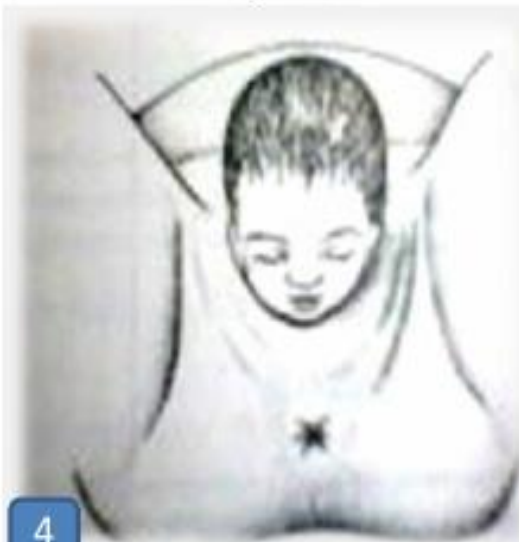
2

Sub-Occipito frontal diameter distending the Vulval Outlet



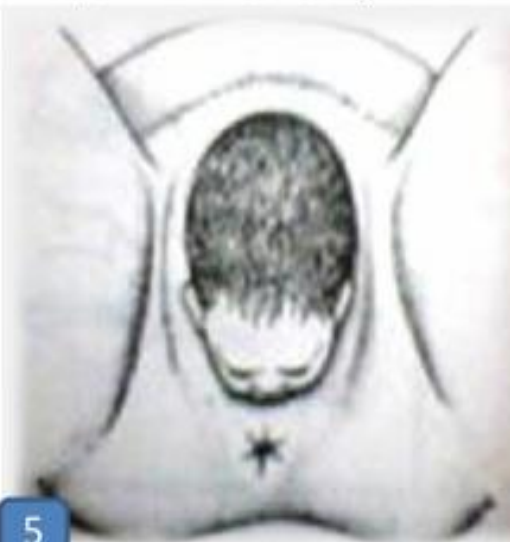3

Assisted Delivery of the Head by Extension, exerting an upward pressure to the chin by the right hand placed over the Anococcygeal plane.



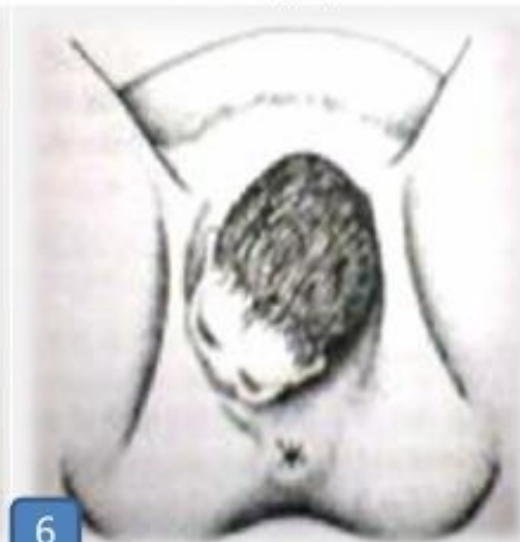4

Head is born by extension



5

Head drops down with the Face close to the anus



6

Restitution